

Webinar – 13th March 2024, Module 2



CASSA

**CARDIAC ARRHYTHMIA SOCIETY
OF SOUTHERN AFRICA**

A SPECIAL INTEREST GROUP OF SA HEART[®]

Essential ECGs

ECGs that matter

Moderator: Philasande Mkoko
Sunninghill Hospital



Rob Scott Millar & Ashley Chin
University of Cape Town / Groote Schuur Hospital
Cape Town, South Africa

Essential ECGs – module 2

Did you attend
Module 1 yesterday?

1. Yes?

2. No?



CASSA
CARDIAC ARRHYTHMIA SOCIETY
OF SOUTHERN AFRICA

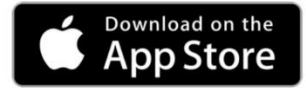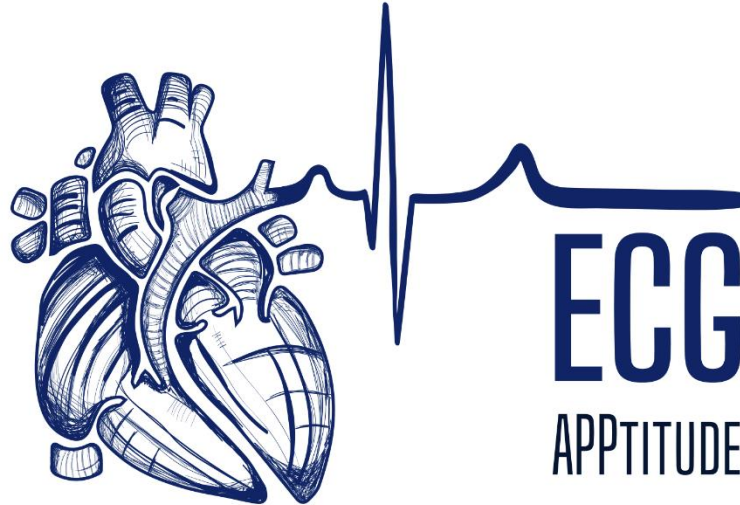
A SPECIAL INTEREST GROUP OF SA HEART [®]

Summary

- Approach to ECG analysis
 - Overview
 - Rate, rhythm (regular or irregular), QRS width
 - Systematic analysis
- Examples of essential ECGs (Module 1)
 1. Normal
 2. Complete heart block
 3. Mobitz II 2nd degree AV block
 4. Inferior and anterior ST elevation myocardial infarction
 5. Atrial fibrillation
 6. Right bundle branch block
 7. Left bundle branch block
- This module: 7 more ECGs

- Free download
- The app was developed by Dr Charle Viljoen of UCT, with help from Rob Scott Millar and many others.
- A teaching and reference tool.
- You will find answers to a lot of your questions in this app
- The app has been redesigned and updated.
- The new version includes searchable terms and clinical correlations
- Available in English, French, German, Portuguese and Spanish.
- More than 32,000 downloads within days of release

Free app for download

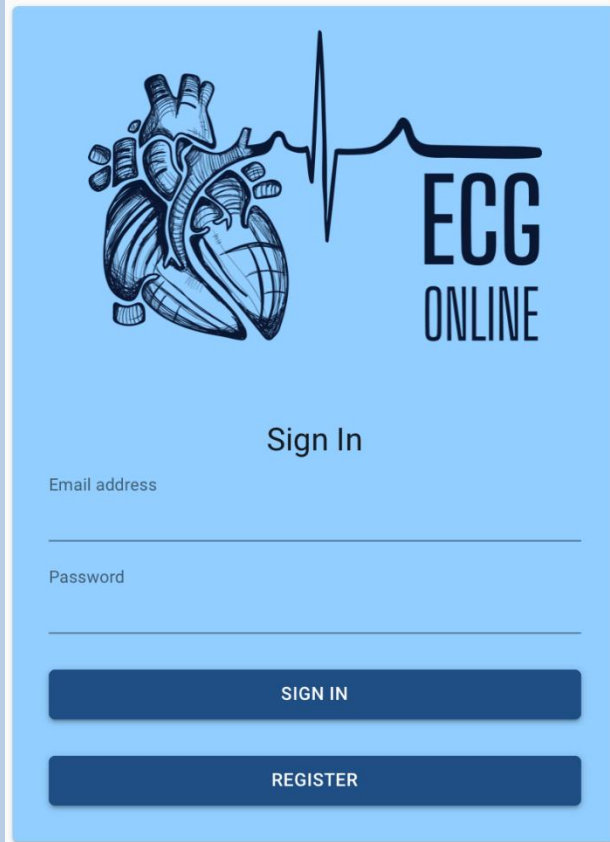


Comprehensive ECG reference guide, with diagnostic approaches for arrhythmias and abnormal waveforms



© University of Cape Town

ecgonline.uct.ac.za



This is now available free outside UCT. There are presently 5 modules of 5-6 ECGs each. It is structured so that you must analyse each ECG systematically. The findings are then summarised and you are asked to choose a diagnosis. This is followed by feedback with the correct diagnosis plus a downloadable pdf with teaching points. You may go back and repeat an ECG at any time or move on. Use it in conjunction with ECGApptitude.

Step 1
Rhythm analysis

Step 2
Waveform analysis

P wave

PR interval

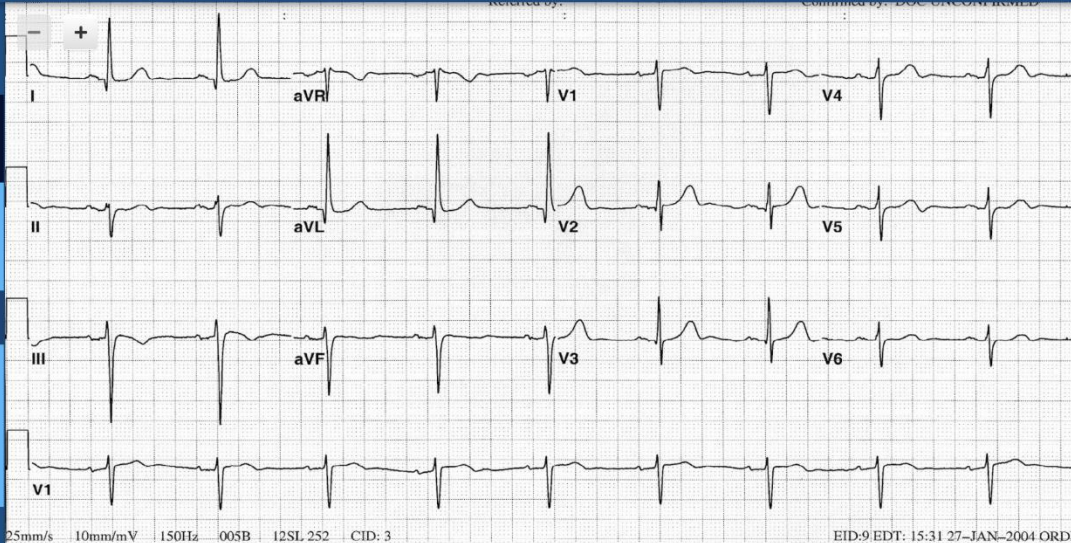
QRS complex

ST segment

T wave

QT interval

Step 3
Conclusion



Clinical scenario

A 74 year old woman is admitted for elective knee replacement. Prior to the surgery an ECG is done and the Anaesthetist asks your opinion.

Summary of analysis

Regular
Narrow complex
Bradycardia with a ventricular rate of 54

P wave upright in II / inverted in aVR
P wave before every QRS complex
QRS complex after every P wave
Normal P wave morphology

Constant PR interval measuring 160 ms
The PR interval is normal

QRS width 80 ms
Normal QRS morphology
QRS axis -45 degrees
Left axis deviation
Poor R wave progression

QRS width

80 ms

QRS axis

-45 degrees

Normal morphology

- Complete RBBB
- Incomplete RBBB
- Complete LBBB
- Incomplete LBBB
- Atypical / bizarre wide QRS
- Delta waves
- J waves
- Epsilon waves
- Variable QRS morphology

- Normal axis
- Right axis deviation
- Left axis deviation
- Extreme axis deviation

- Normal R wave progression
- Poor R wave progression
- Dominant R in V1
- Increased left ventricular voltage
- Low QRS amplitude

Sample ECG

- Pathological Q in inferior leads
- Pathological Q in anterior leads
- QS complexes in lateral leads
- Premature narrow complex
- Premature wide complex
- Narrow escape beat / rhythm
- Wide escape beat / rhythm
- Capture beat
- Fusion beat
- Electrical alternans

The ECG can be enlarged for closer inspection



The ECG Atlas of Cardiac Rhythms

This book contains around 95 full size 12 lead ECGs which are analysed in detail. It covers all the rhythms you are likely to see in practice grouped into:

- Bradycardias and conduction disturbances
- Abnormal rhythms at normal rates (including paced)
- Narrow QRS tachycardias
- Wide QRS tachycardias

Rob Scott Millar

To get the book, go to: <http://www.ecgrhythmsatlas.com/>

What can you learn from an ECG?

- Rhythm
- Conduction
- Structural heart disease
 - Myocardial infarction
 - Hypertrophy
 - Atria
 - Ventricles
 - Pericarditis
- Transient abnormalities
 - Ischaemia
 - Electrolytes

Who should have an ECG?

- Acute chest pain
- Arrhythmia
- Suspected heart disease
- Chest pain
- Unexplained blackouts
- Hypertension
- Major medical/surgical illness
- Drug overdose
- Stroke
- Patients over 50
- Routine check up

Looking at the ECG

Primary observations


- **Ventricular rate:**
 - Normal (60 – 100/minute)
 - Slow (<60/minute)
 - Fast (>100/minute)
- **Regularity:**
 - Regular
 - Irregular
- **QRS width**
 - Normal ($\leq 100\text{ms}$)
 - Wide ($\geq 120\text{ms}$)
 - Left bundle branch block
 - Right bundle branch block
 - Neither
 - Delta wave

Secondary observations

- **P waves**
 - Present or absent/not visible
 - Morphology (? Upright in II, negative aVR)
 - Rate
 - Relationship to QRS complexes
- **PR interval**
- **QRS abnormalities**
- **ST segments**
- **T waves**
- **QT interval**

You see only what you look for You recognise only what you know

(Merrill C Sosman - Radiologist 1890-1959)



MERRILL CLARY SOSMAN, M.D.

Steps in analysing the ECG

- **Observe and measure**
 - Rate
 - Regularity
 - QRS width
 - Any obvious abnormalities
- **Systematic analysis**
 - P waves
 - PR interval
 - QRS complexes
 - ST segments
 - T waves
 - QT

- **Interpret**
 - Normal/abnormal
 - Possible mechanisms of abnormalities
 - Consider the differential diagnosis
 - Exclude the impossible
- **Conclude**
 - Rhythm
 - Structural abnormalities
 - Alternative diagnoses
 - Possible underlying pathology

Summarise

Main features
Likely diagnosis

Communicate

your findings clearly and
succinctly

Beware snap (“blink”) diagnoses and hasty conclusions which lead to premature closure

Look beyond the obvious – analyse systematically

What is a normal ECG?

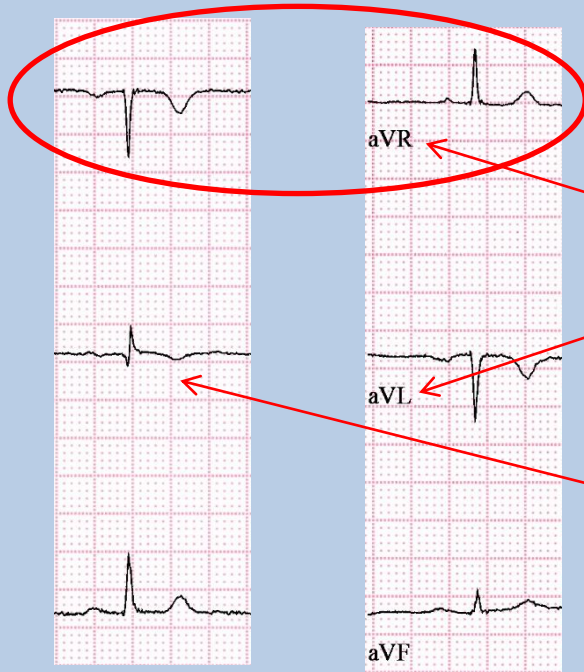- Normal sinus rhythm
- Normal PR interval
- QRS normal
 - Duration
 - Size
 - Axis
 - No pathological q waves
- Normal ST segments and T waves
- Normal QT interval
- Minor deviations usually benign

Normal Adult ECG values

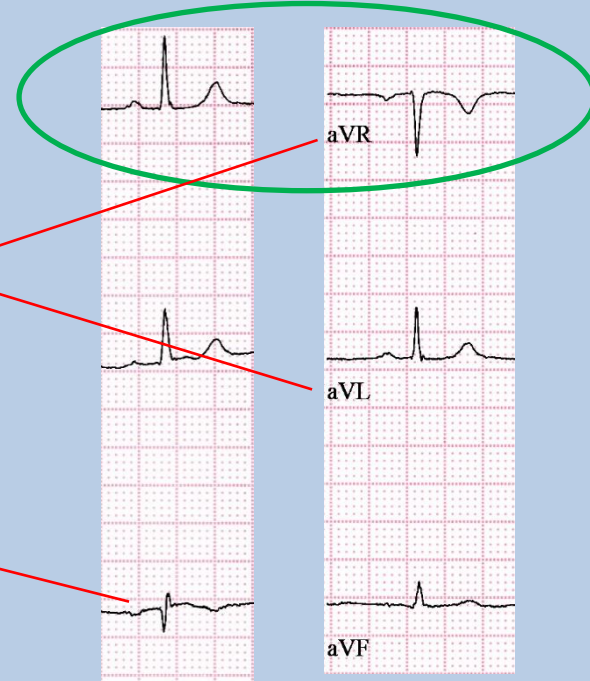
- P wave
 - Axis: $+30^{\circ}$ to $+70^{\circ}$ (+ve II, -ve aVR)
 - Duration $\leq 110\text{ms}$
- PR interval:
 - 120 to $\leq 200\text{ms}$ (3-5 small blocks)
- QRS
 - Duration: $\leq 100\text{ms}$ (≤ 2.5 small blocks)
 - Axis: $+0^{\circ}$ to $+90^{\circ}$ (0° to -30° grey zone)
 - Size: S in V1 + R in V5/V6 $\leq 3.5\text{mV}$ (35mm)
 - R in aVL $\leq 1.1\text{mV}$ (11mm)
- QTc
 - $\leq 440\text{ms}$ (males)
 - $\leq 460\text{ms}$ (females)

Incorrect lead placement

Left-right arm leads reversed

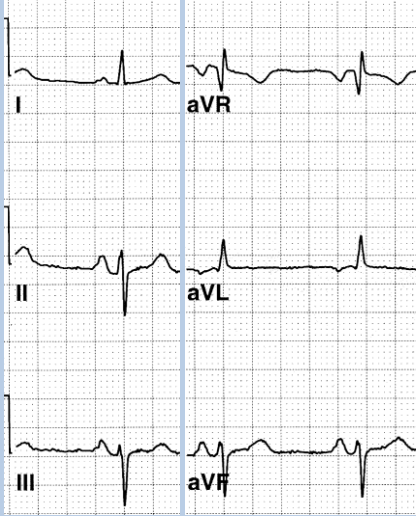


Leads correct



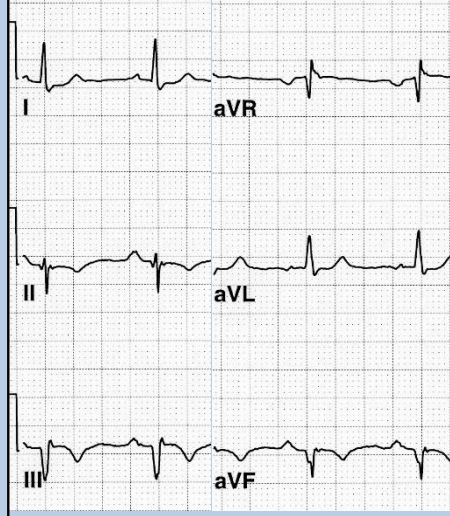
Mechanisms of left axis deviation

Left anterior fascicular block



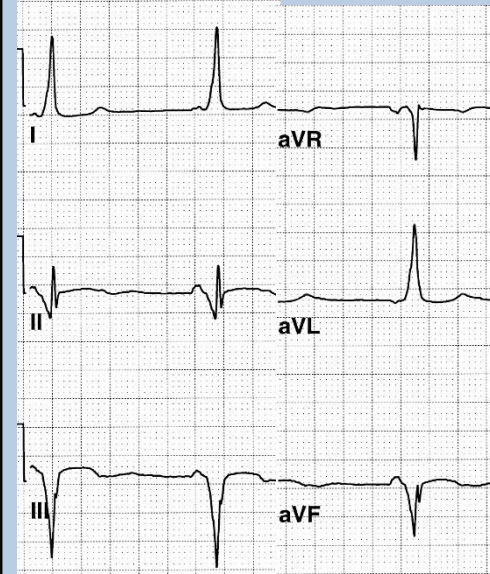
- QRS axis -50° ($< -30^{\circ}$)
- Small r waves II, III, aVF
- Small q waves I, aVL
- QRS width normal
- Terminal S waves II, III, aVF

Old inferior myocardial infarction



- QRS axis -50°
- Broad ($\geq 30\text{ms}$) q waves II, III, aVF
- Terminal r waves II, III, aVF

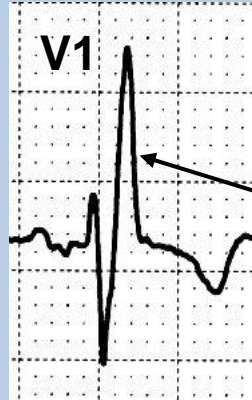Wolff-Parkinson-White pattern



- QRS axis -40°
- Short PR interval – 100ms
- Wide QRS – 140ms
- Initial slurred delta wave – negative in II, III, aVF – simulates inferior MI

Typical patterns of right & left bundle branch block

RBBB



V1 & V2 positive
rSR' in V1

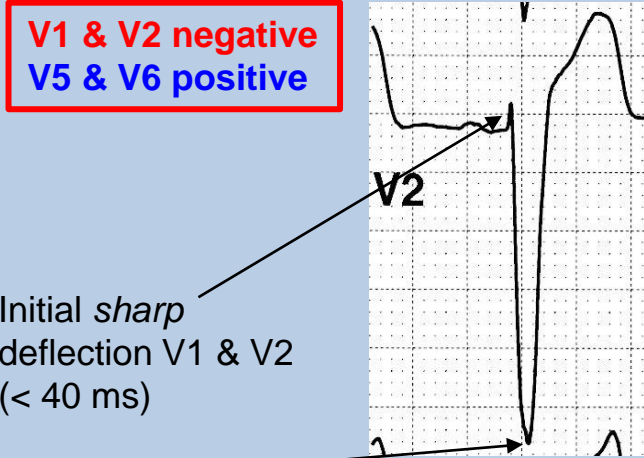
Broad *terminal* R in V1



Normal left ventricular activation (septal q, rapid R upstroke in V6)

Small ₁ broad terminal s in V6

LBBB



V1 & V2 negative
V5 & V6 positive

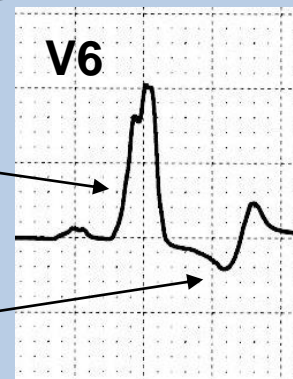Initial *sharp* deflection V1 & V2 (< 40 ms)

Onset to nadir of S wave < 70ms

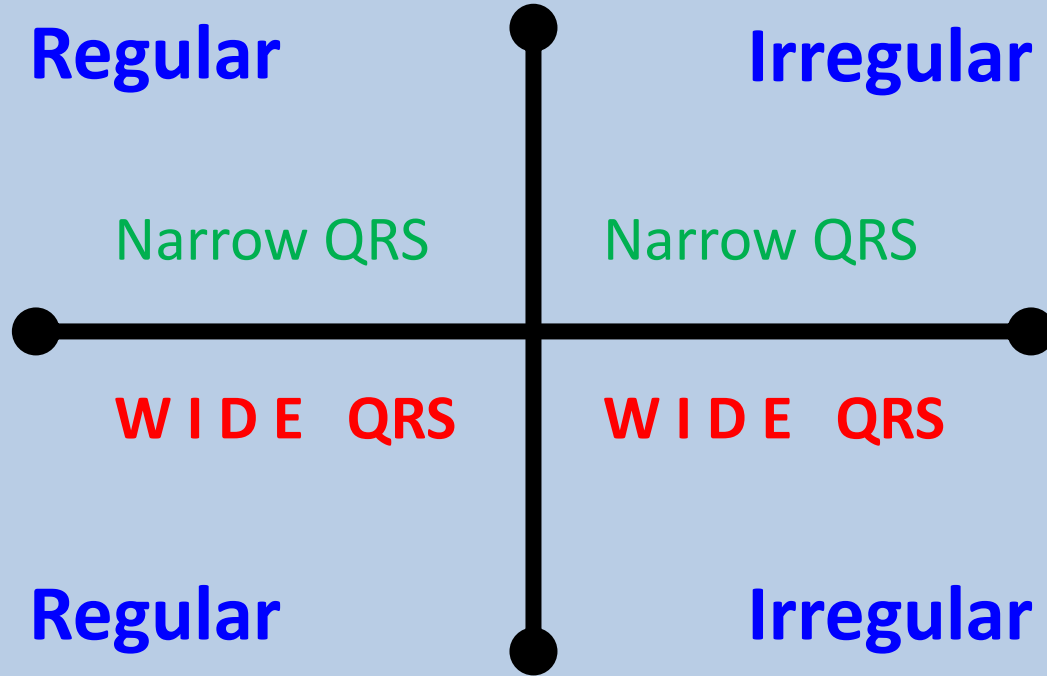
Slurred R wave

Absent septal q wave

Inverted T wave



TACHYARRHYTHMIAS



TACHYARRHYTHMIAS

Regular

Narrow QRS

- Sinus tachycardia
- **Atrial flutter**
- **AV nodal re-entry tachycardia**
- Atrioventricular re-entry tachycardia (WPW)
- Atrial tachycardia
- Junctional ectopic tachycardia

Irregular

Narrow QRS

- **Atrial Fibrillation**
- **Atrial flutter/tachy + variable AV block**
- Multifocal atrial tachycardia

- **Ventricular tachycardia**
 - SVT with bundle branch block
 - SVT with non-specific intraventricular conduction delay
 - Antidromic AV re-entry tachycardia
 - Pre-excited SVT
 - Paced rhythm
- } WPW

- **AF with BBB**
- **A flutter/tachy + variable AV block + BBB**
- Pre-excited AF (WPW)
- Polymorphic VT
- Repetitive monomorphic VT

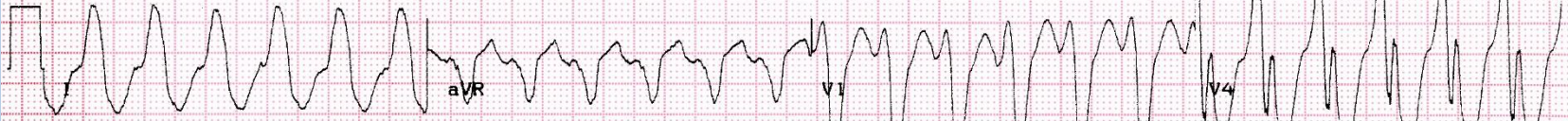Regular

WIDE QRS

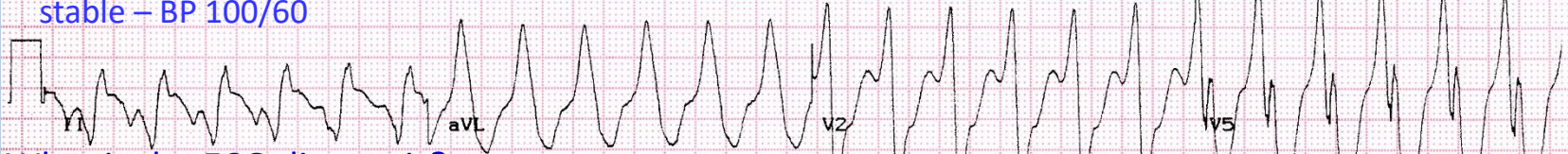Irregular

WIDE QRS

ECG 8

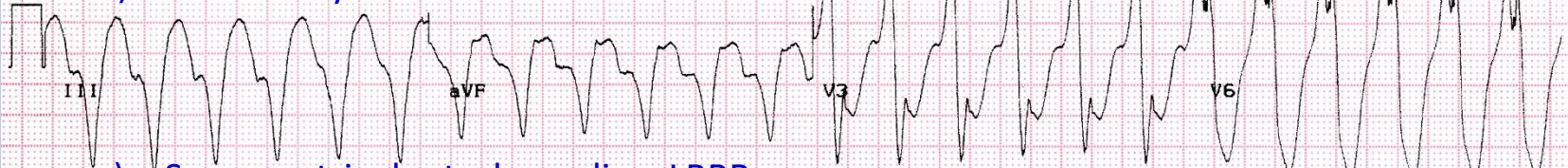

This 74year old woman presents with sudden onset of rapid palpitations. She was haemodynamically stable – BP 100/60

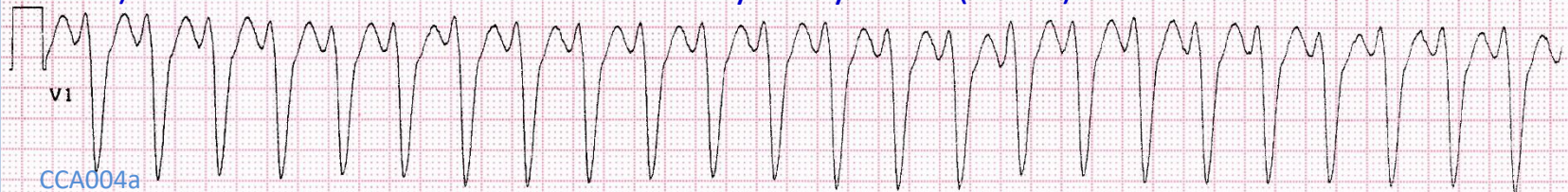

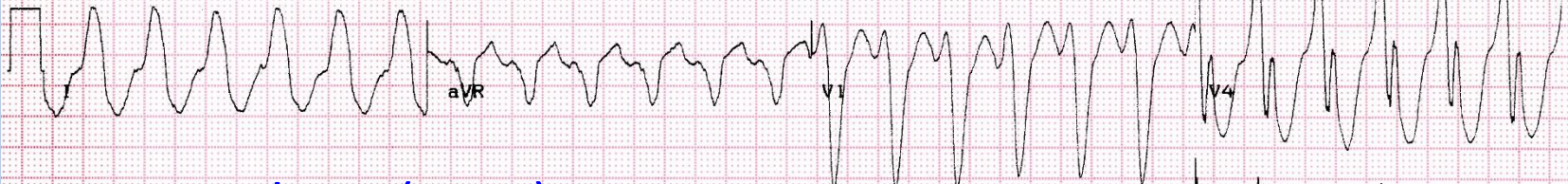What is the ECG diagnosis?:

- a) Ventricular tachycardia
- b) Sinus tachycardia + LBBB

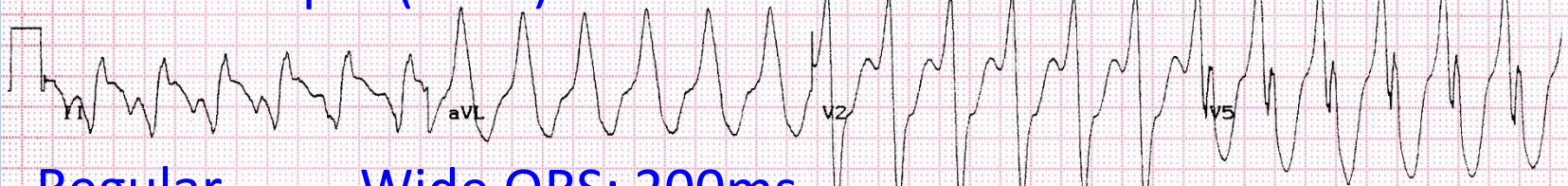

- c) Supraventricular tachycardia + LBBB
- d) Antidromic atrioventricular re-entry tachycardia (WPW)



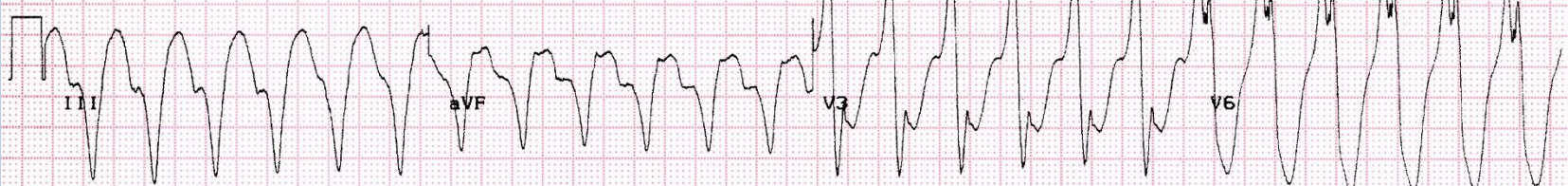

Fast: 144bpm (24x6)

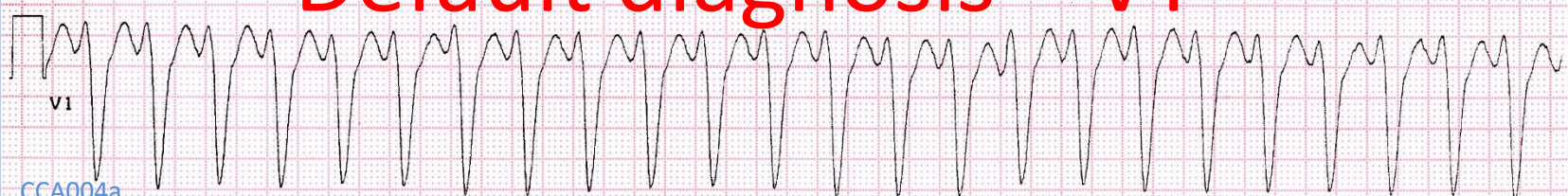

Regular

Wide QRS: 200ms

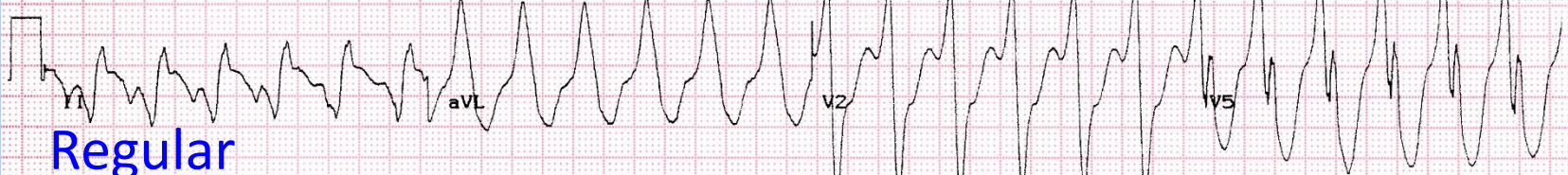

Default diagnosis = VT



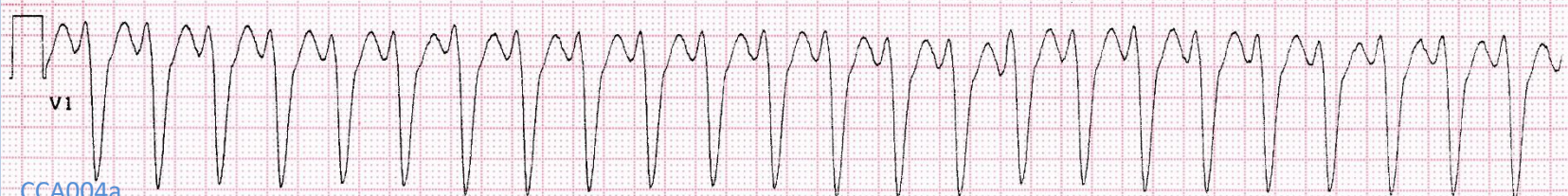
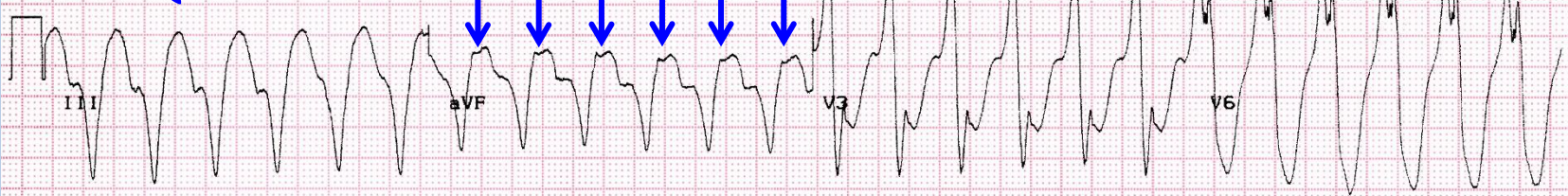


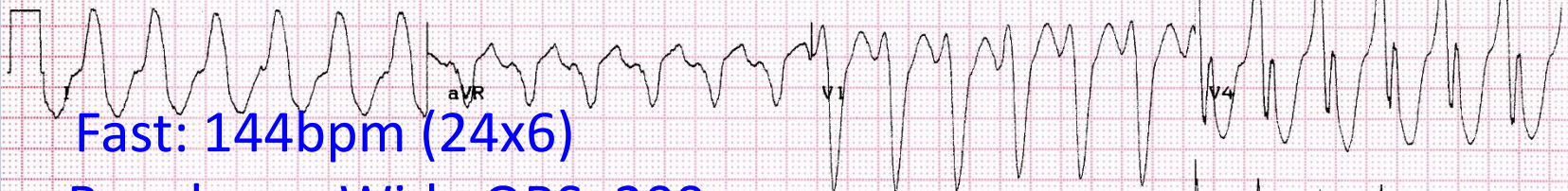Fast: 144bpm (24x6)



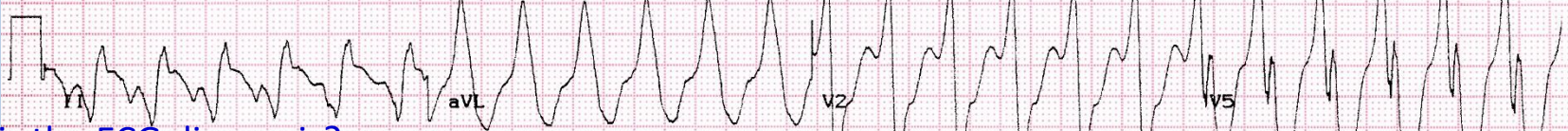Regular

Wide QRS: 200ms



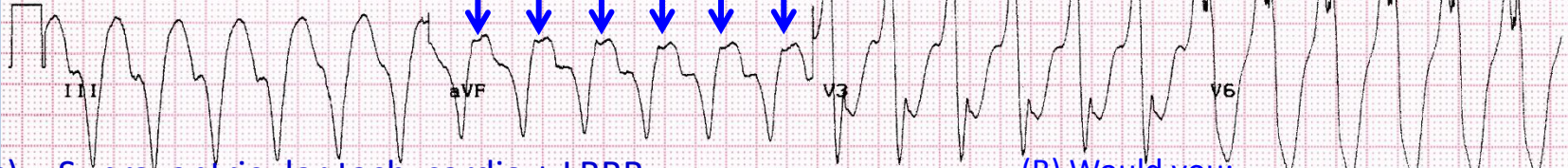


Regular Wide QRS: 200ms



What is the ECG diagnosis?:

- a) Ventricular tachycardia
- b) ~~Sinus tachycardia + LBBB~~

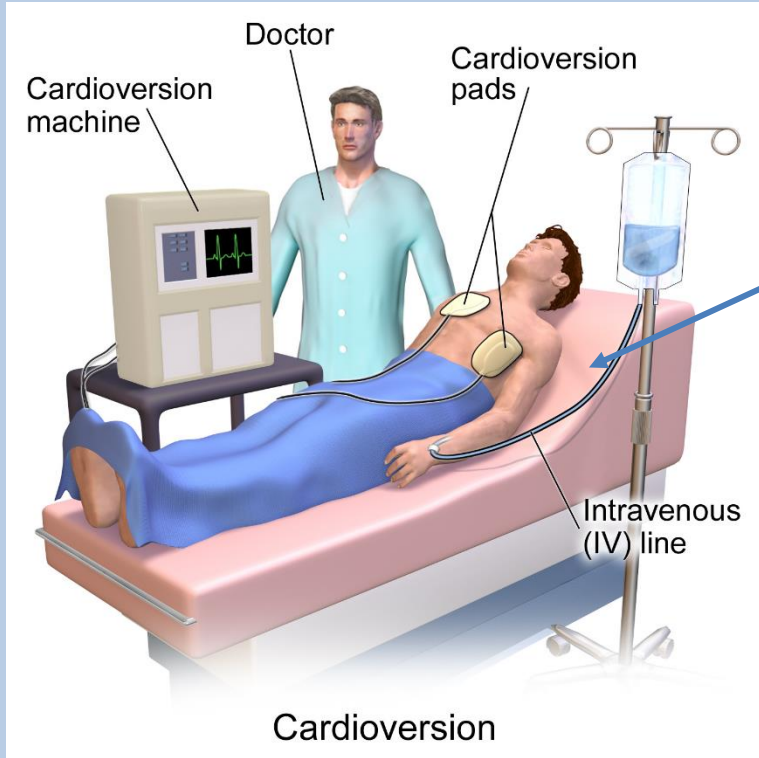


- c) Supraventricular tachycardia + LBBB
- d) Antidromic atrioventricular re-entry tachycardia (WPW)

(B) Would you:

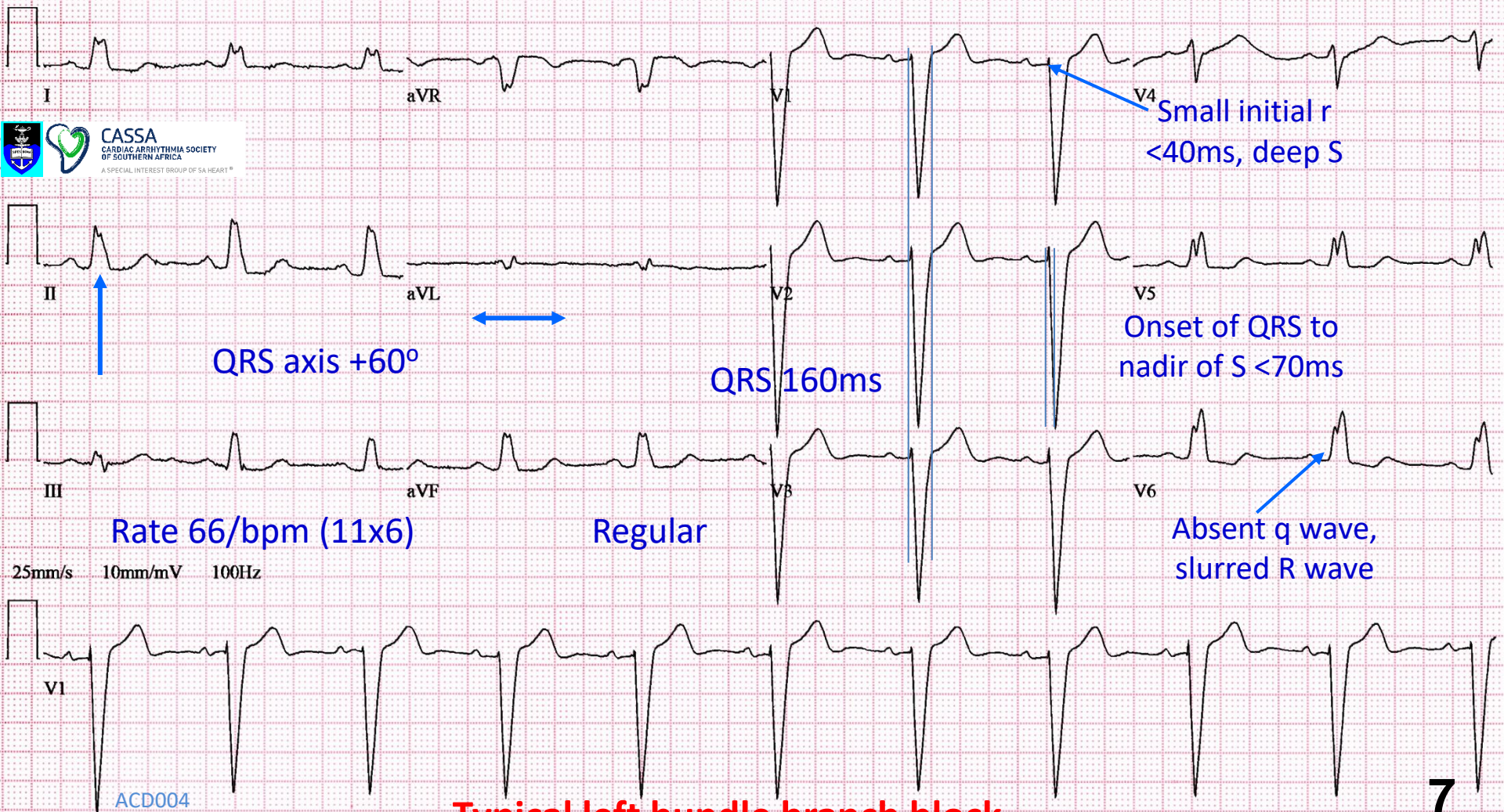
- a. Give IV adenosine
- b. Give IV verapamil
- c. Cardiovert electrically
- d. Give IV lignocaine
- e. Give IV amiodarone

Synchronised DC cardioversion

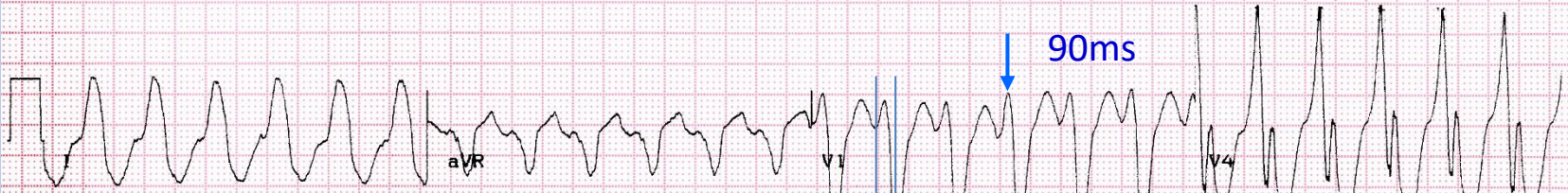


- Resuscitation equipment
- Reassure the patient
- Consent
- Set up
- Check synchronisation to R wave
- Midazolam IV until patient is asleep
- Check patient's airway/breathing
- Set power to 150J/200J (biphasic shock)
- Start recording ECG (preferably 3 channels)
- Recheck synchronisation
- Deliver shock
- Check ECG rhythm and vital signs
- Do 12 lead ECG

Wikipedia: Blausen.com staff (2014). "[Medical gallery of Blausen Medical 2014](#)"

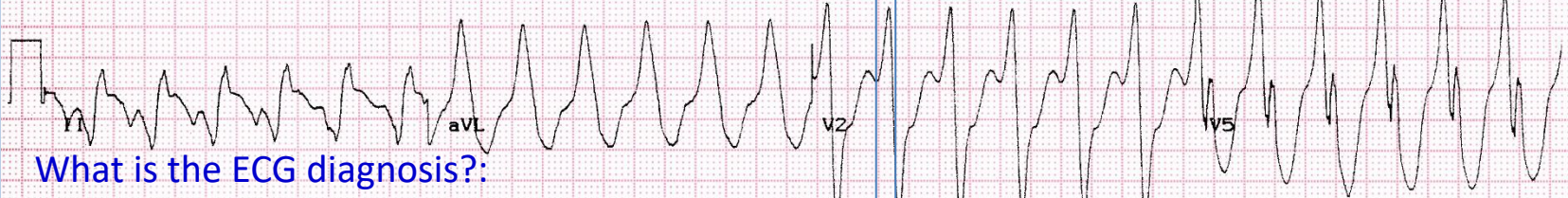

Typical left bundle branch block



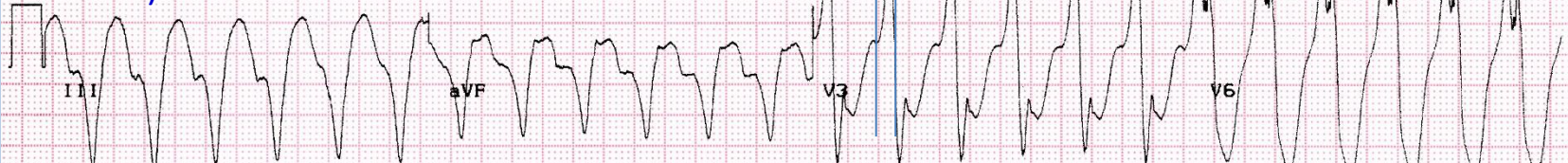Onset of QRS
to nadir of S

130ms

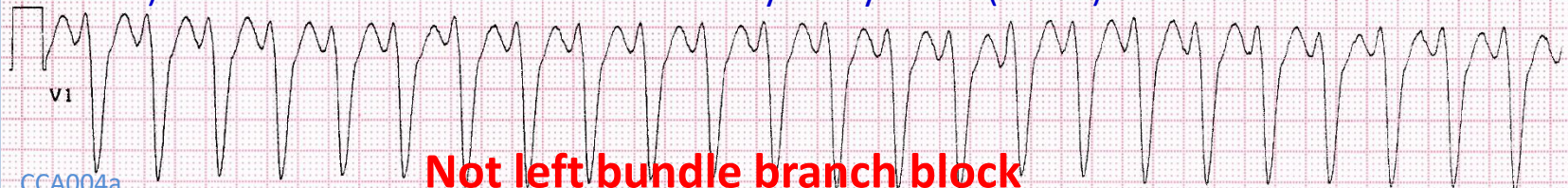


What is the ECG diagnosis?:

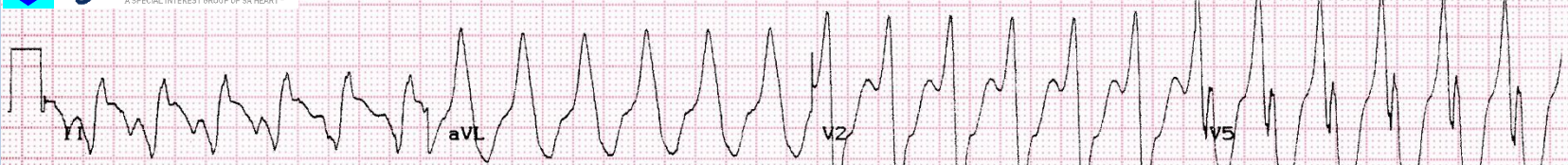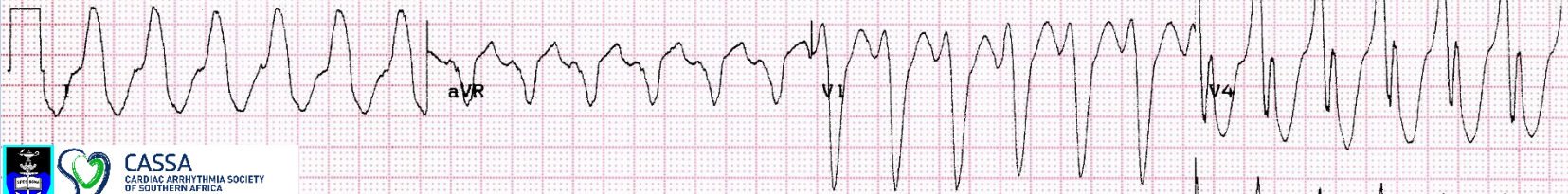- a) Ventricular tachycardia
- b) -----



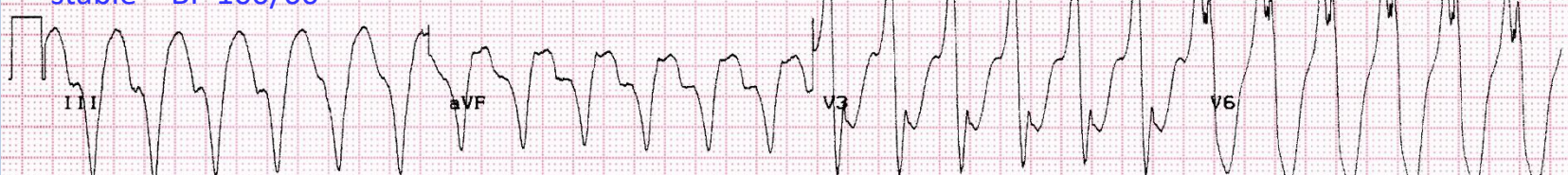- c) ~~Supraventricular tachycardia + LBBB~~
- d) Antidromic atrioventricular re-entry tachycardia (WPW)



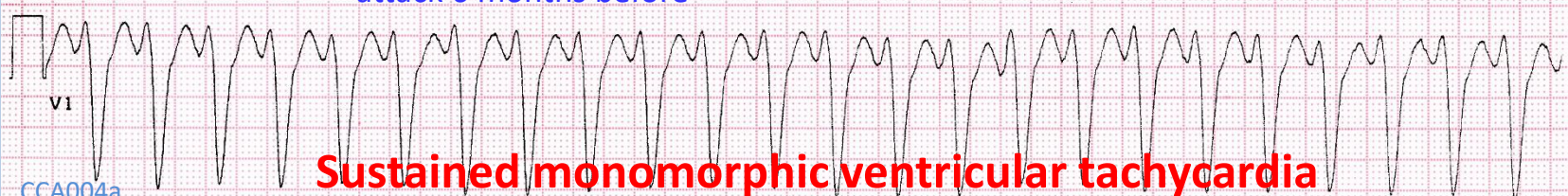
Not left bundle branch block



This 74 year old woman presents with sudden onset of rapid palpitations. She was haemodynamically stable – BP 100/60

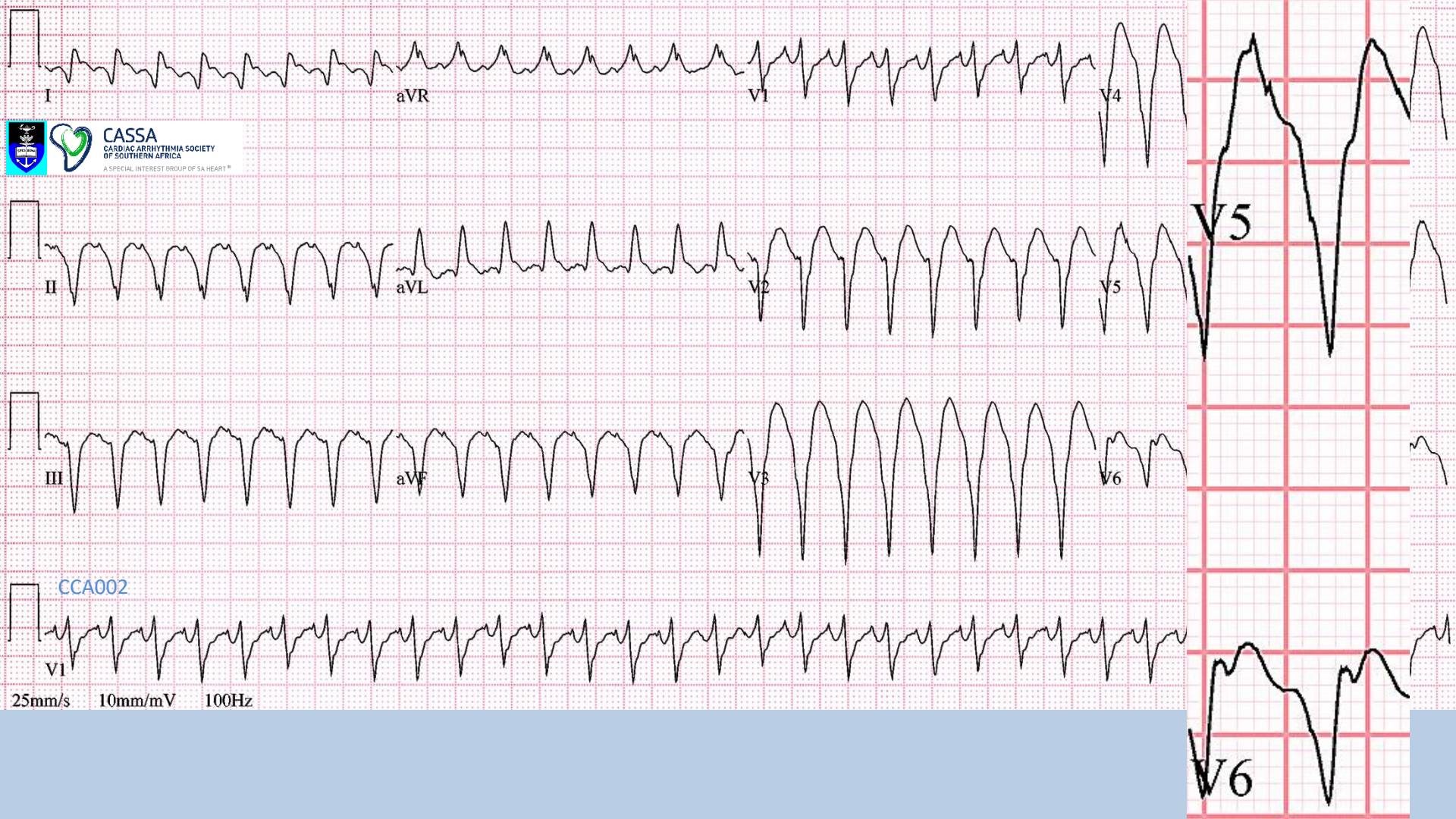


She gives a history of being admitted for a heart attack 6 months before



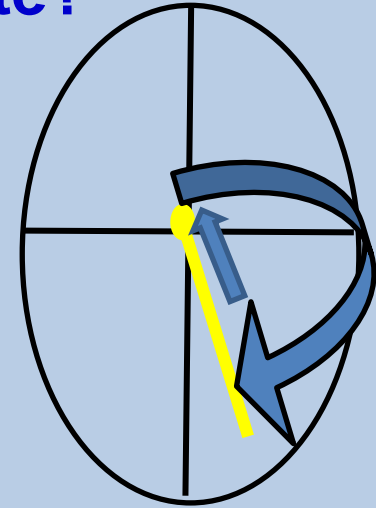
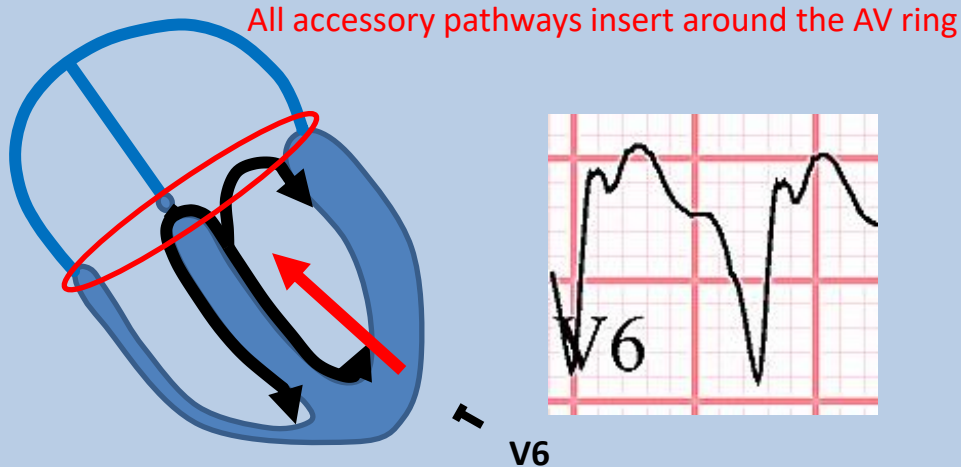
Sustained monomorphic ventricular tachycardia

CCA004a



Ventricular tachycardia or antidromic AVRT how do we differentiate?

- ECG features:
 - AV dissociation: if present, it excludes AVRT, confirms VT
 - QS pattern V4-V6 – excludes AVRT



Antidromic AVRT (uncommon)
There must be a 1:1 AV
relationship

– If neither, it may be impossible to differentiate on ECG alone

Regular wide QRS tachycardia

Default diagnosis is ventricular tachycardia

Typical bundle branch block

Yes

Probably SVT

Some VT's have relatively typical BBB patterns:
Idiopathic left fascicular tachycardia
Idiopathic RV outflow tract tachycardia
Bundle branch re-entry tachycardia

Yes

Pacemaker mediated tachycardia (low probability)

SVT with non-specific IV conduction delay (low probability)

Need other information

No

QS complexes V5-6

VT

No

AV dissociation

Yes

VT

No

VT

Antidromic AVRT

Need other information

Ventricular tachycardia or antidromic AVRT

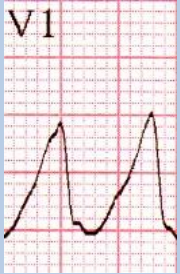
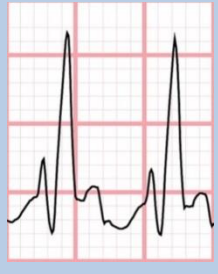
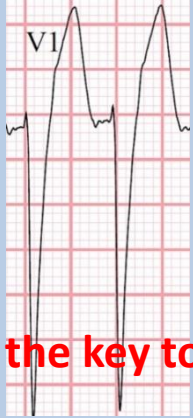
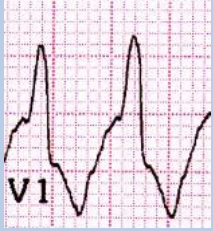
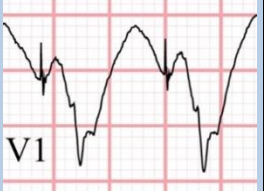
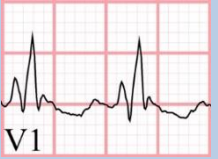
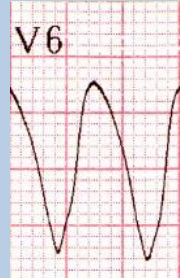



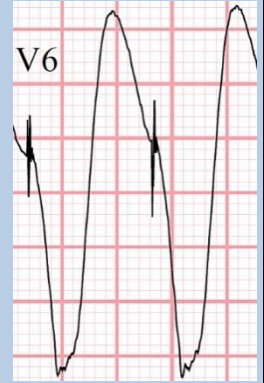

how do we differentiate?

- ECG features:
 - AV dissociation: if present, it excludes AVRT, confirms VT
 - QS pattern V4-V6 – excludes AVRT
 - If neither, it may be impossible to differentiate on ECG alone
- **Clinical context**
 - History of past MI – presence of substrate raises probability of VT to >95%
 - Age
 - Youth favours AVRT, but VT can occur from infancy to senility
 - Family history
- ECG in sinus rhythm
 - Delta waves confirm WPW
 - Pathological Q waves of old MI confirm VT, but beware pseudo-infarct patterns in WPW
 - Other: e.g. ARVC patterns, conduction problems (sarcoid)
- Other tachycardia ECGs
 - AV dissociation
 - Different QRS pattern favours VT

Regular wide QRS tachycardias

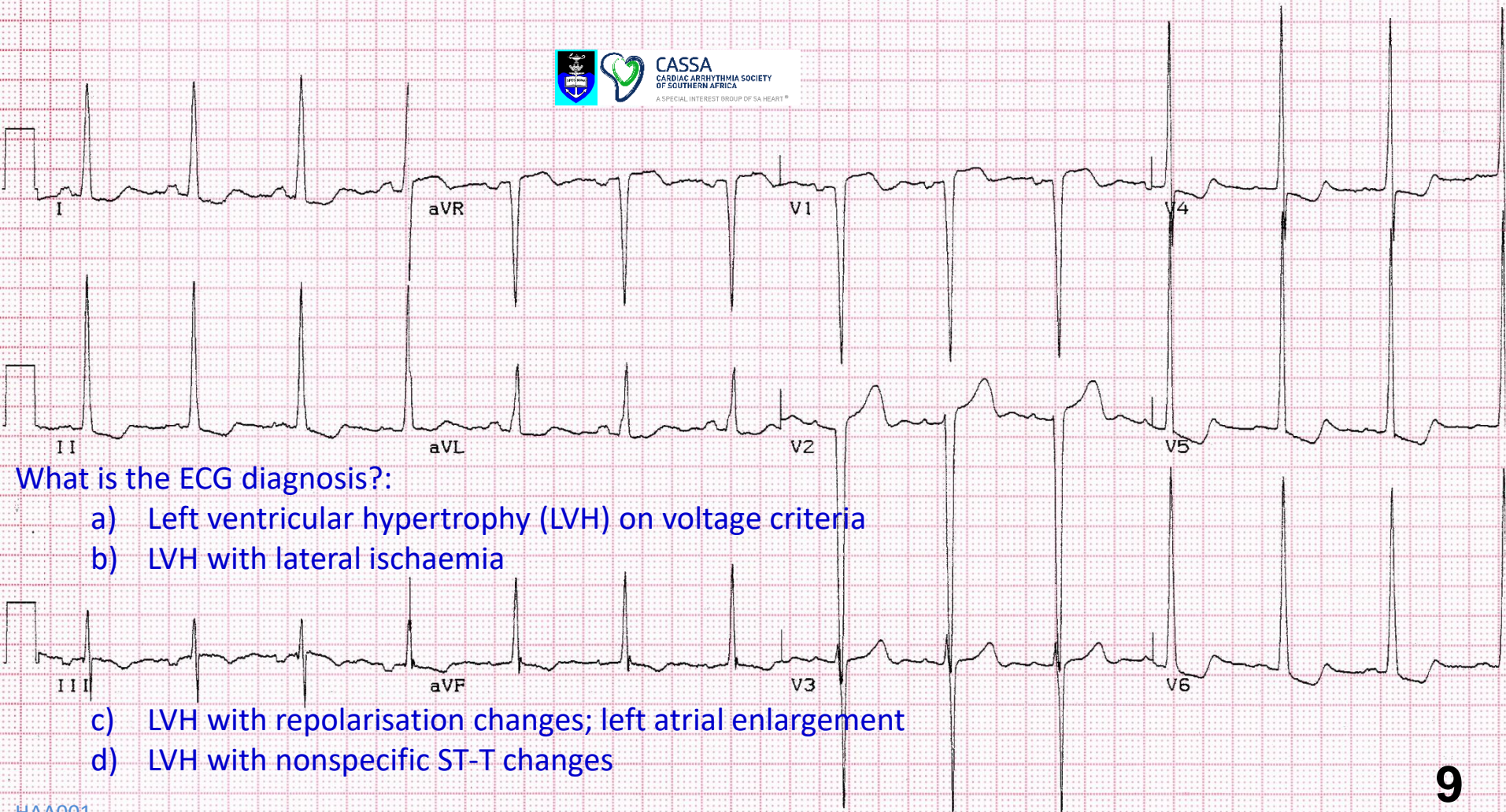
- **Ventricular tachycardia**
- Supraventricular tachycardia with bundle branch block
- Antidromic AVRT
 - WPW
 - Mahaim tachycardia
- Pre-excited SVT (e.g. atrial flutter)
- Ventricular paced rhythm
- SVT with nonspecific intraventricular conduction delay

Mechanisms of wide QRS complexes in tachycardias

Ventricular origin	Supraventricular origin + RBBB	Supraventricular origin + LBBB	Supraventricular origin + pre-excitation (WPW)	Ventricular paced	Supraventricular origin + non-specific diffuse IVCD
					
					


QRS morphology is the key to diagnosis of wide QRS tachycardias

ECG 9



What is the ECG diagnosis?:

- a) Left ventricular hypertrophy (LVH) on voltage criteria
- b) LVH with lateral ischaemia
- c) LVH with repolarisation changes; left atrial enlargement
- d) LVH with nonspecific ST-T changes



P negative > ,04mV

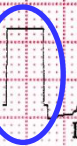

P wave 120ms
bifid

Rate 78/bpm (13x6)

Regular

QRS 80ms



S in V1+R in V5 = 67mm

S in V1=30mm

R in V5=37mm

R in aVL=12mm

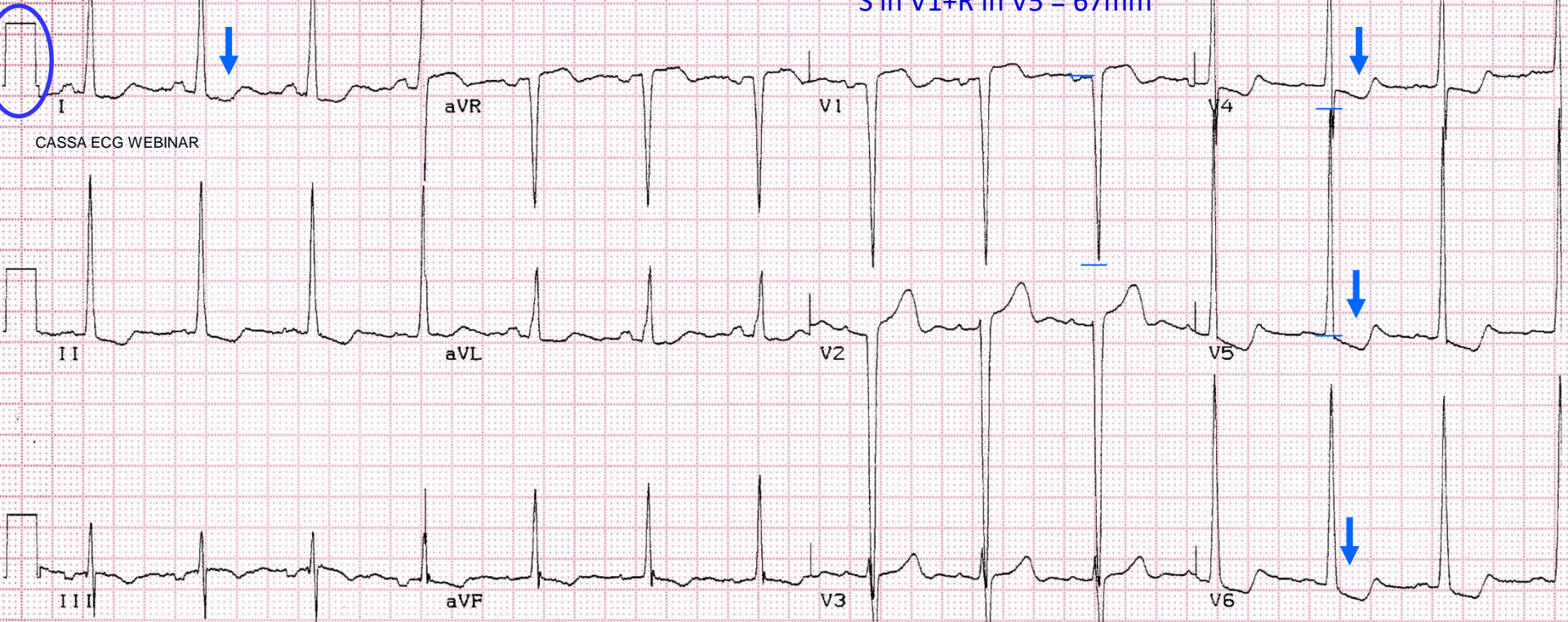
R in aVL + S in V3 = 37mm

S in V3=25mm

ECG Criteria for Left Ventricular Hypertrophy Aged 40 years and older

- Sokolow-Lyon:
 - S in $V1$ + R in $V5$ ($V6$) $>$ 3,5mV (35mm)
 - R in aVL $>$ 1,1mV (11mm)
- Cornell:
 - S in $V3$ + R in aVL $>$ 28 mm (men)
 - S in $V3$ + R in aVL $>$ 20 mm (women)

S in V1+R in V5 = 67mm

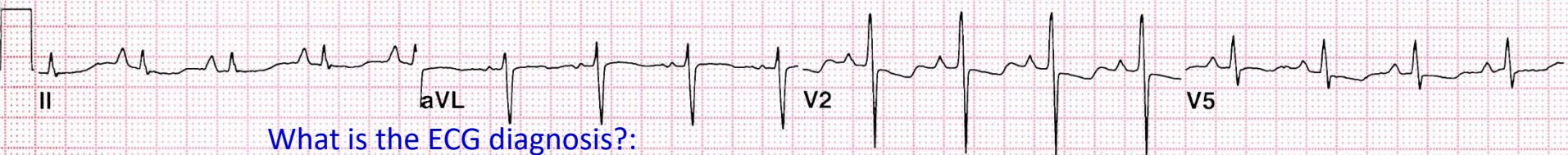
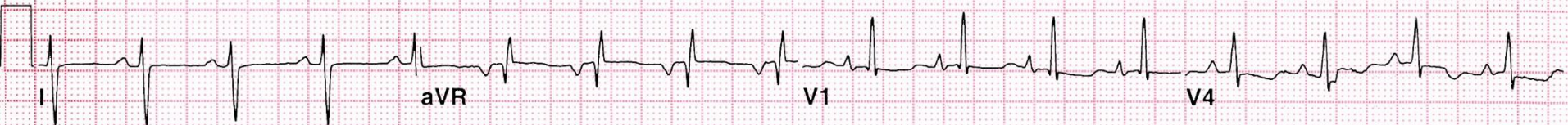
CASSA ECG WEBINAR

R in aVL + S in V3 = 37mm

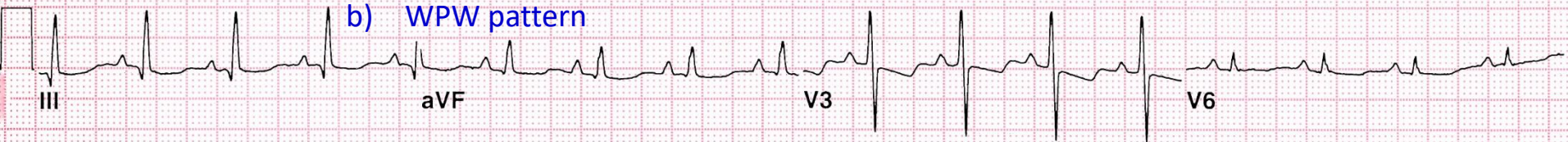LVH with repolarisation changes; left atrial enlargement

ECG 10



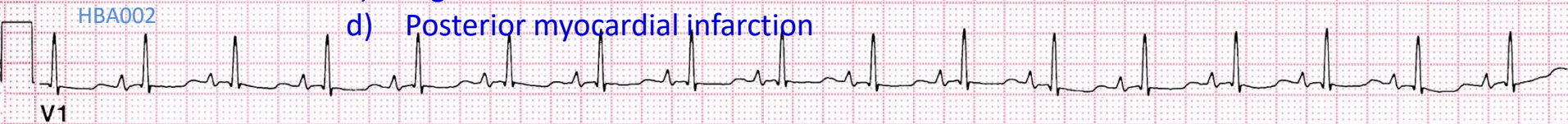What is the ECG diagnosis?:

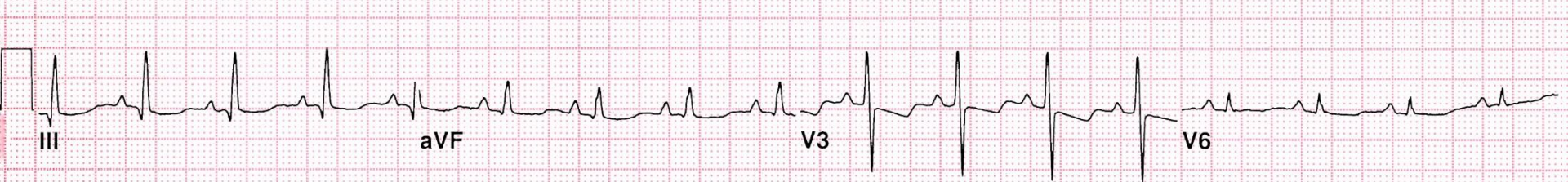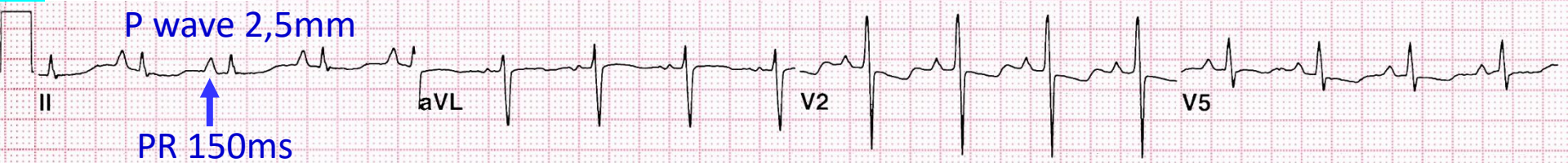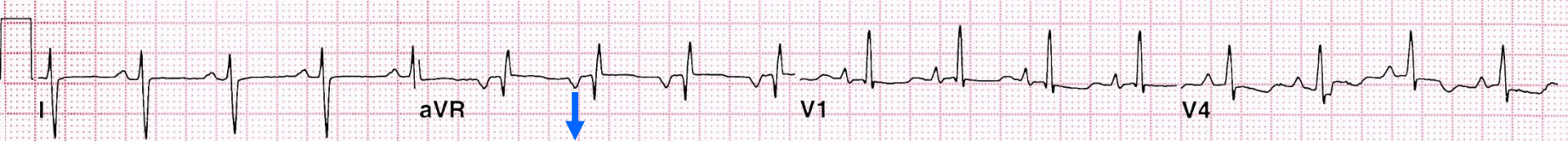- a) Right ventricular hypertrophy
- b) WPW pattern



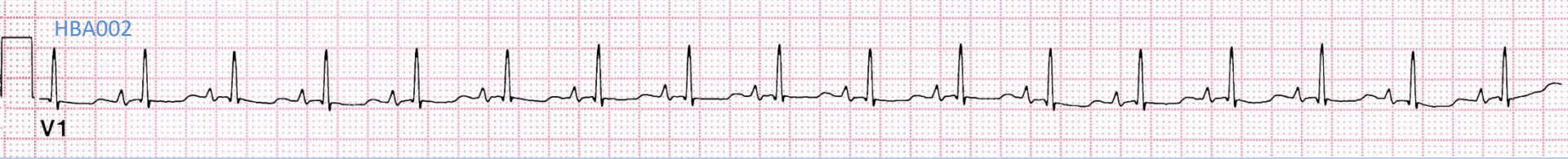25mm/s 10mm/mV 100Hz

- c) Right bundle branch block
- d) Posterior myocardial infarction





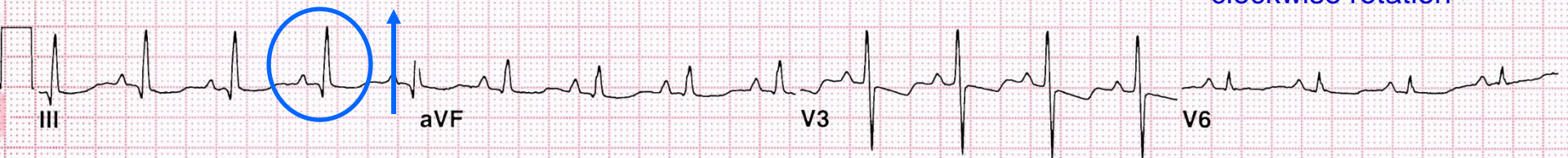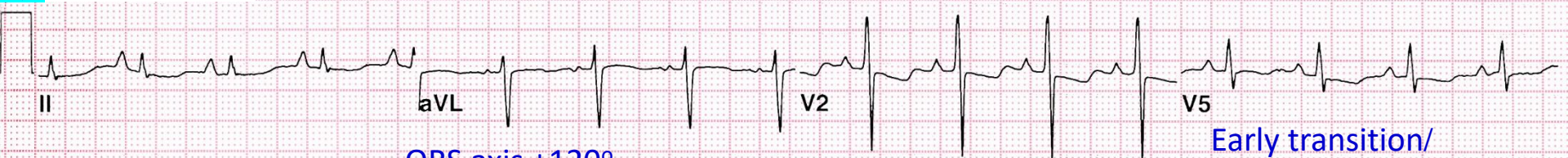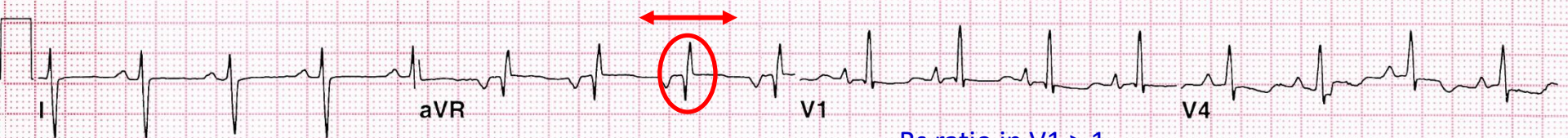25mm/s 10mm/mV 100Hz



Rate 102/bpm (17x6)

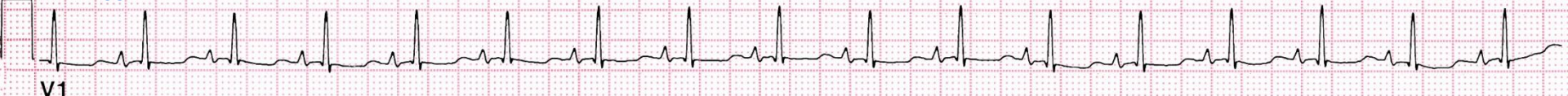Regular

QRS 80ms



25mm/s 10mm/mV 100Hz

HBA002



Rate 102/bpm (17x6)

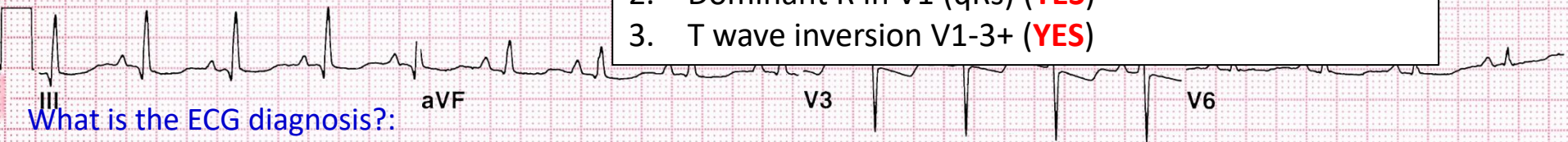
Regular

QRS 80ms



3 criteria to diagnose RVH

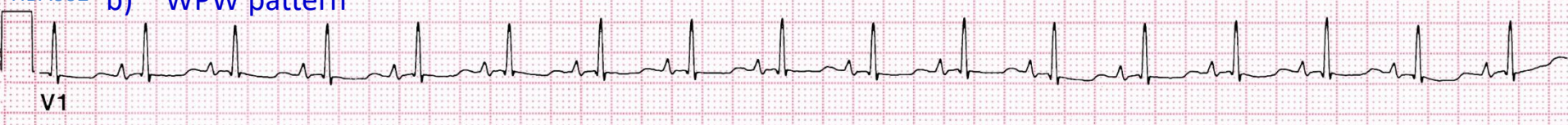1. Right axis deviation (**YES**)
2. Dominant R in V1 (qRs) (**YES**)
3. T wave inversion V1-3+ (**YES**)



What is the ECG diagnosis?:

- a) Right ventricular hypertrophy
- b) WPW pattern

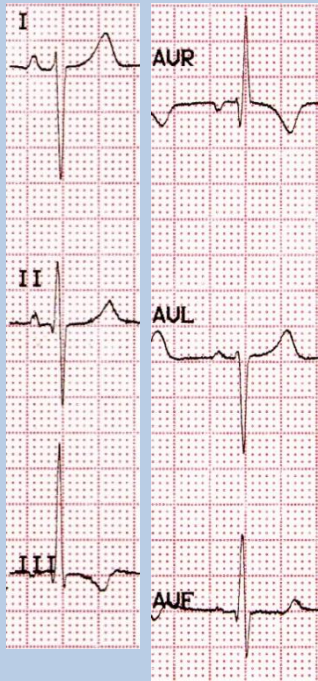
25mm/s
10mm
HBA002



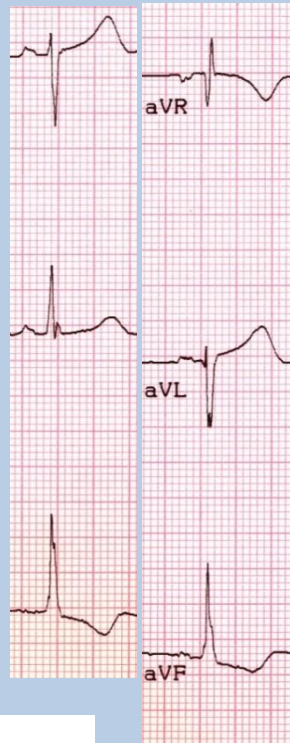
- c) Right bundle branch block
 - d) Posterior myocardial infarction
- Severe right ventricular hypertrophy**

Mechanisms of right axis deviation

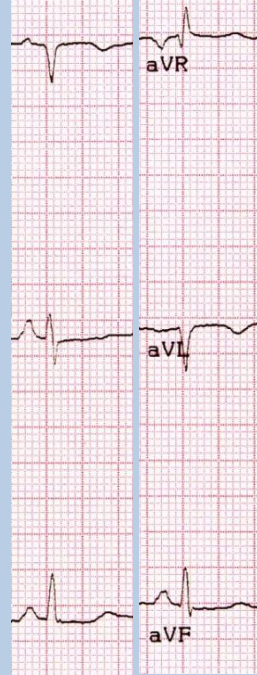
RVH



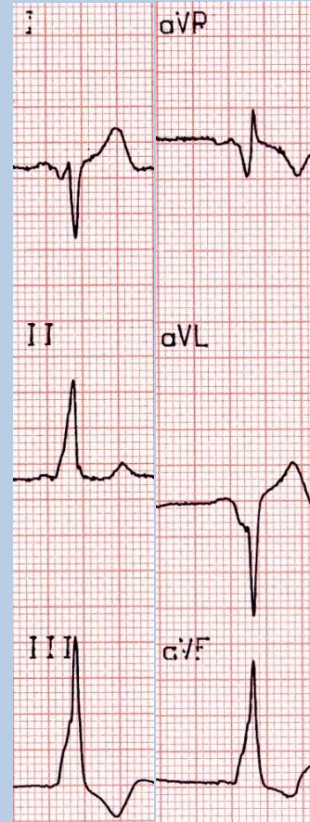
L posterior fascicular block



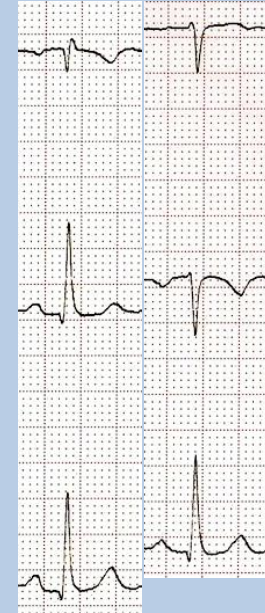
Lateral myocardial infarction



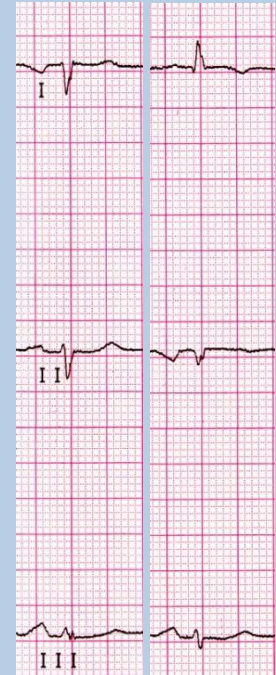WPW pattern



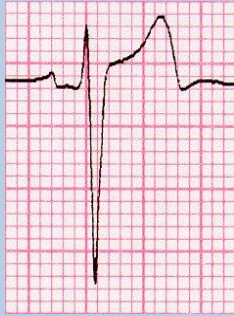
Limb leads misplaced



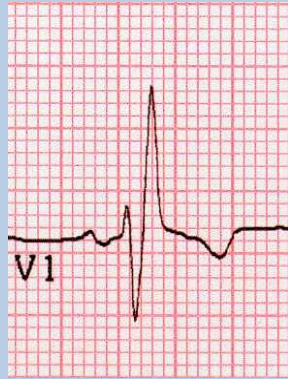Mirror-image dextrocardia



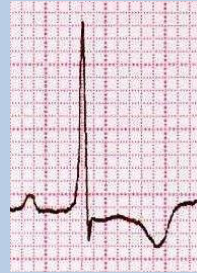Dominant R wave in V1



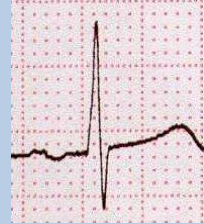
Normal



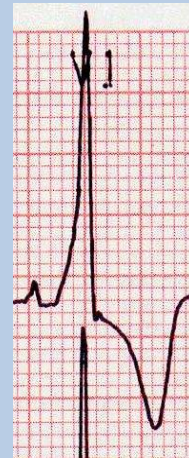
RBBB



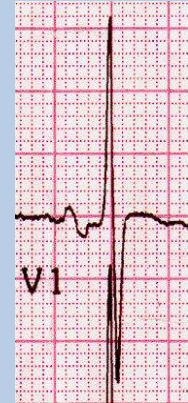RVH



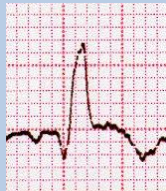
Posterior MI



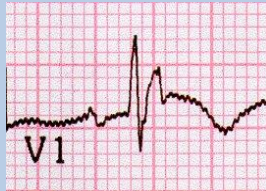WPW



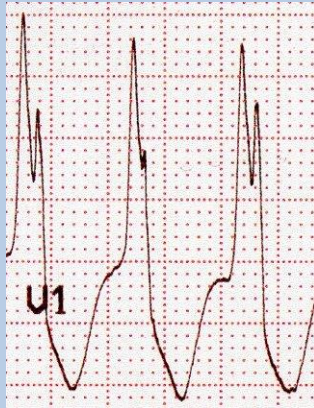Duchenne's



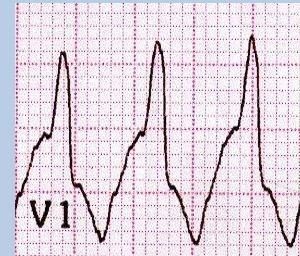
Anterior MI -
RBBB



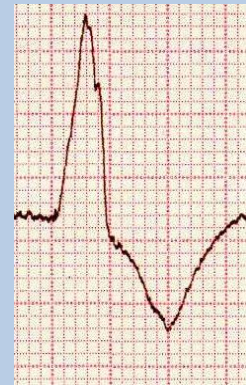ARVC



Ventricular rhythms



Antidromic
tachycardia -
WPW

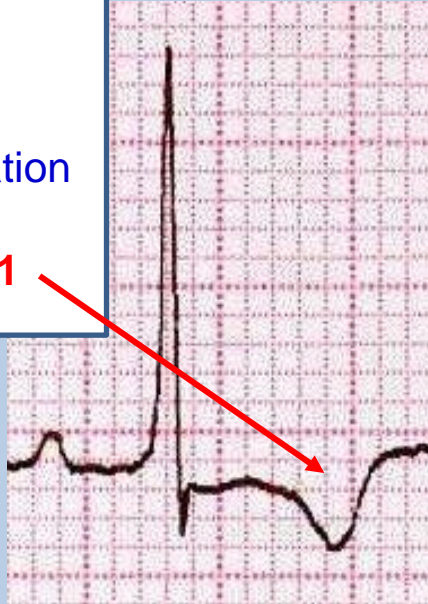


LV pacing

RVH vs posterior MI

RVH:

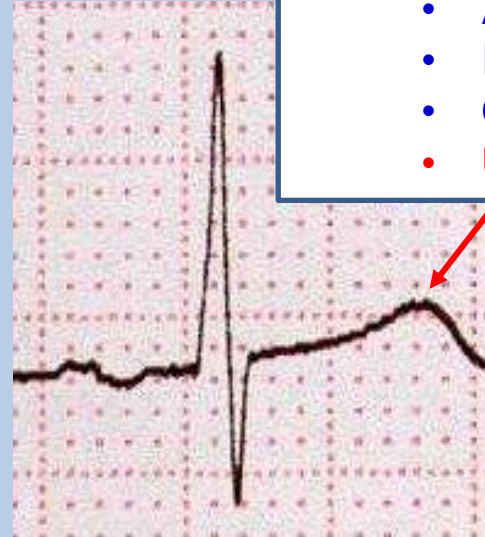- Clinical
 - Depends on cause
 - Signs of RVH
- Echocardiography
- ECG
 - Right axis deviation
 - R>S in V1
 - **Inverted T in V1**



RVH

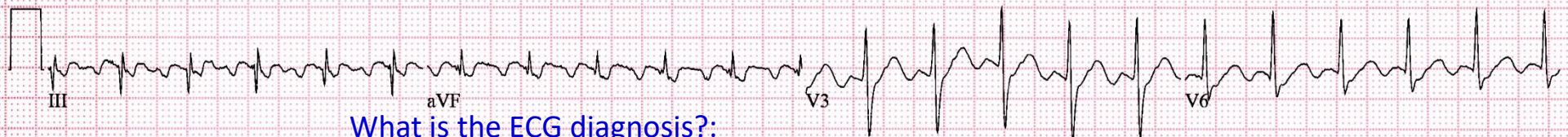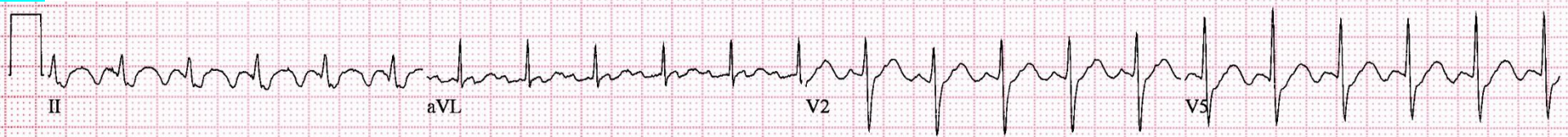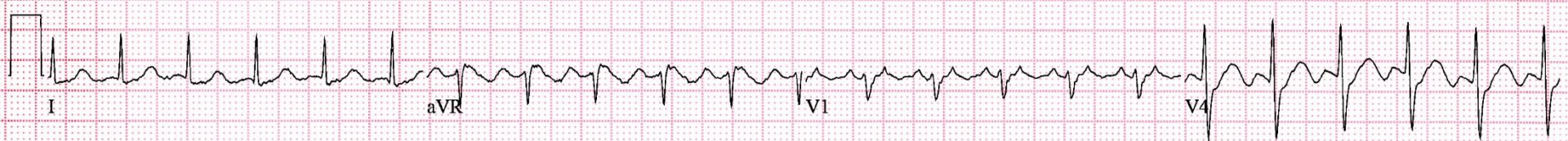Posterior MI:

- Clinical
 - History of chest pain
 - No signs of RVH
- ECG
 - Axis variable
 - R>S in V1
 - Often inferior MI
 - **Upright T in V1**



Posterior MI

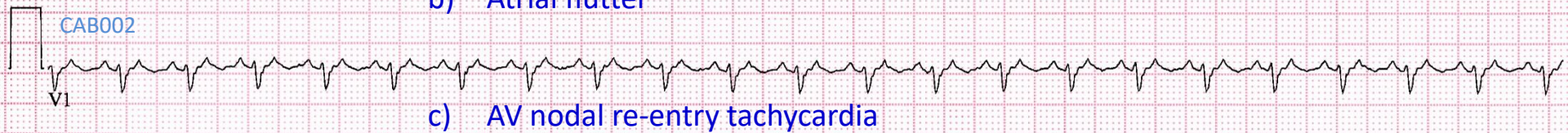
ECG 11



25mm/s 10mm/mV 100Hz

What is the ECG diagnosis?:

- a) Sinus tachycardia
- b) Atrial flutter
- c) AV nodal re-entry tachycardia
- d) AV re-entry tachycardia



CAB002

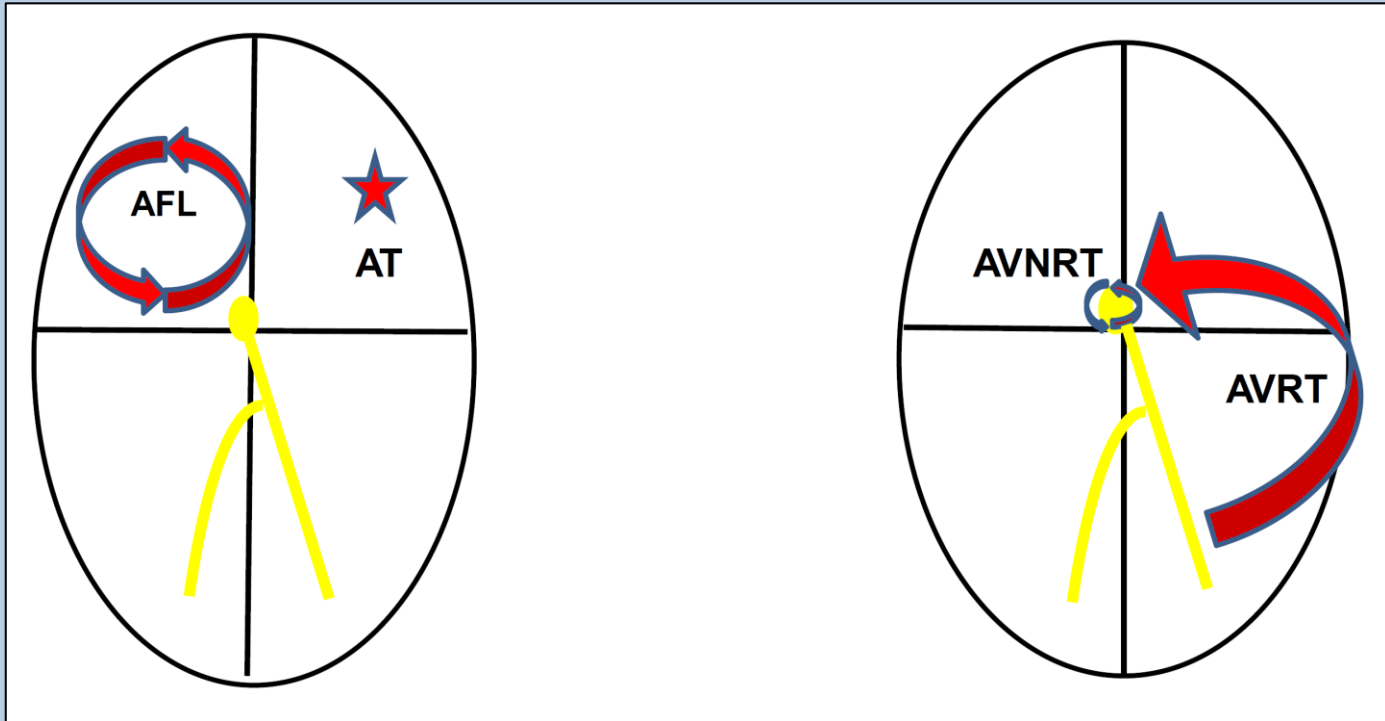
TACHYARRHYTHMIAS

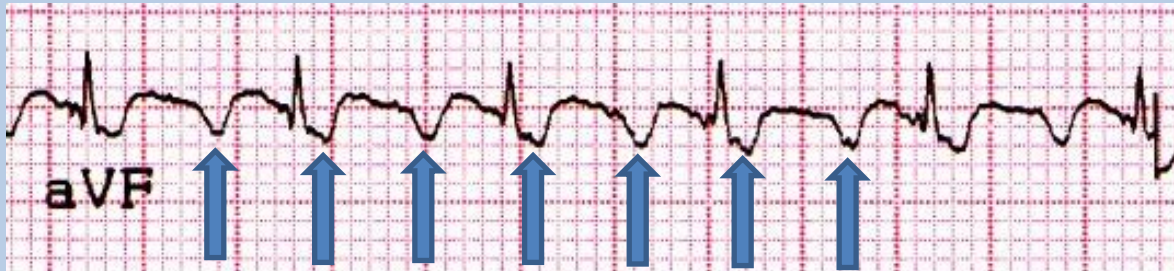
Regular

Narrow QRS

- Sinus tachycardia
- **Atrial flutter**
- **AV nodal re-entry tachycardia**
- Atrioventricular re-entry tachycardia (WPW)
- Atrial tachycardia
- Junctional ectopic tachycardia (infants)


Narrow, complex regular tachycardias



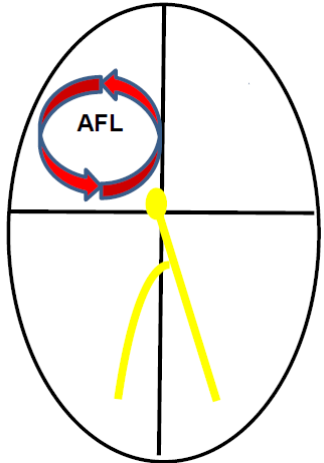


Flutter waves in the inferior leads shows an initial gradual, followed by a deeply negative component and then a terminal positive deflection

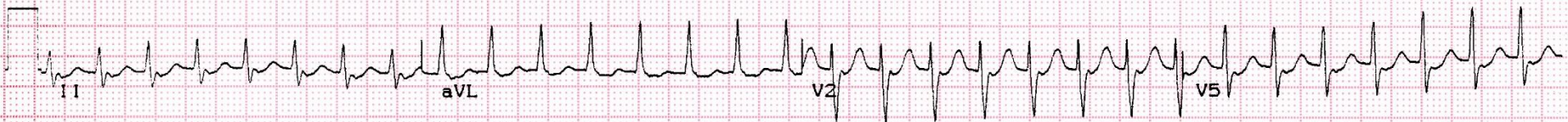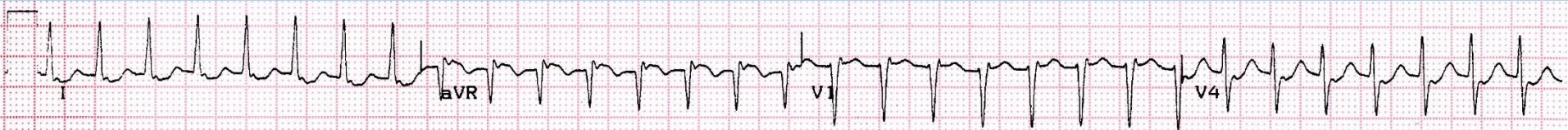Flutter waves usually 240-360bpm with 2:1 AV block



Lead V1 has an initial inverted component followed by an upright component

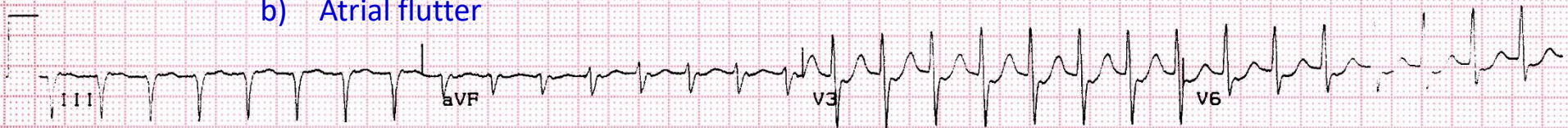

ECG 12

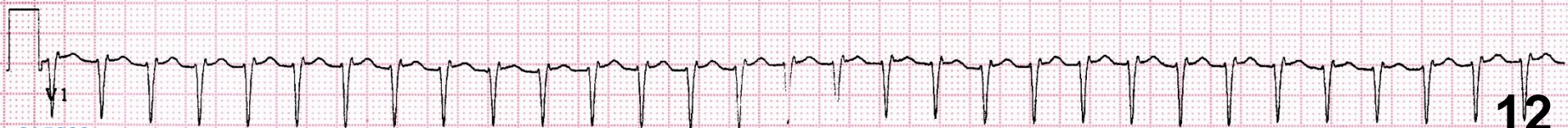

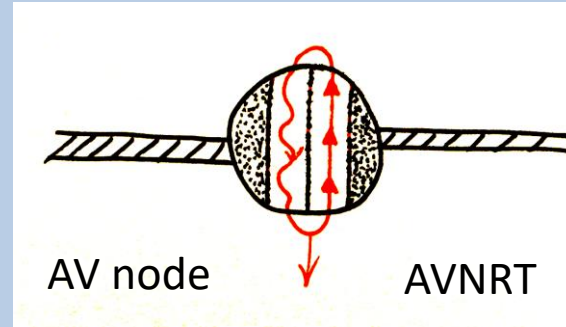
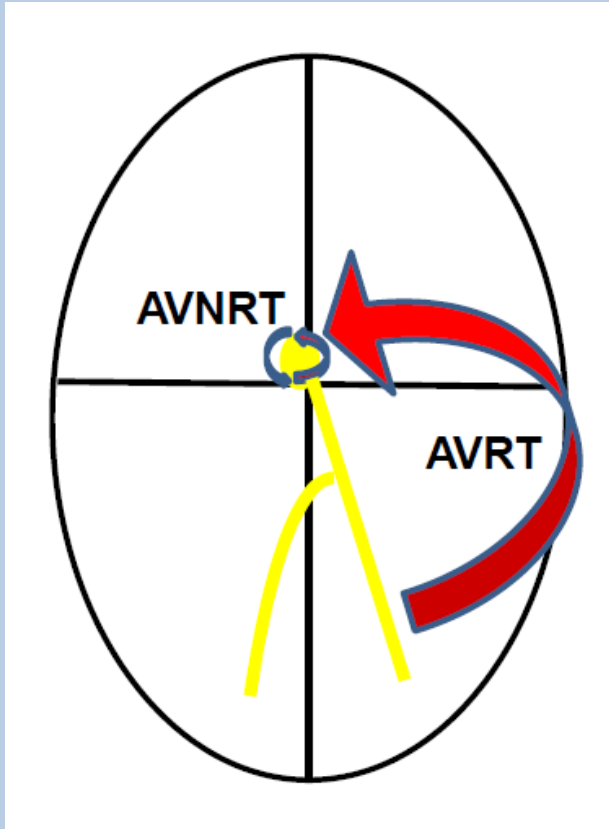
What is the ECG diagnosis?:

- a) Sinus tachycardia
- b) Atrial flutter



- c) AV nodal re-entry tachycardia
- d) AV re-entry tachycardia

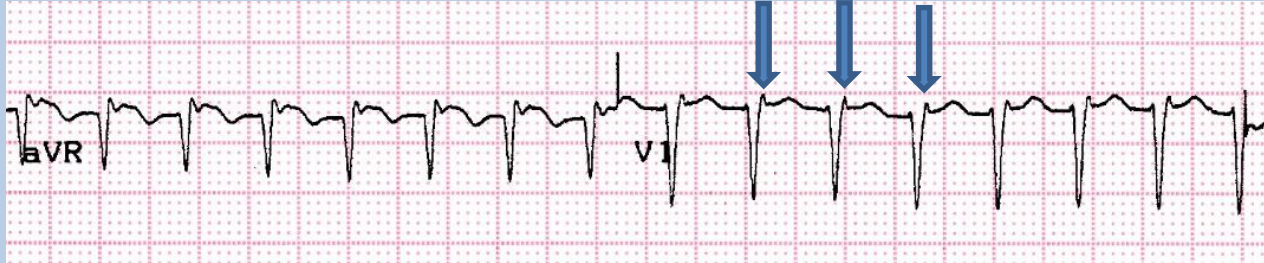



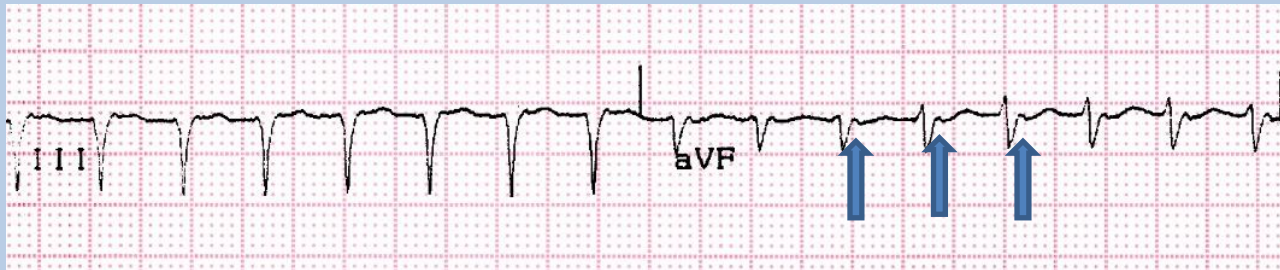Typical AVNRT usually causes a very short RP tachycardia i.e. the QRS complex is followed immediately by a retrograde P wave

Typical AVRT usually causes a short RP tachycardia i.e. the QRS complex is followed by a P wave that is >90ms from the QRS complex.

TYPICAL AVNRT

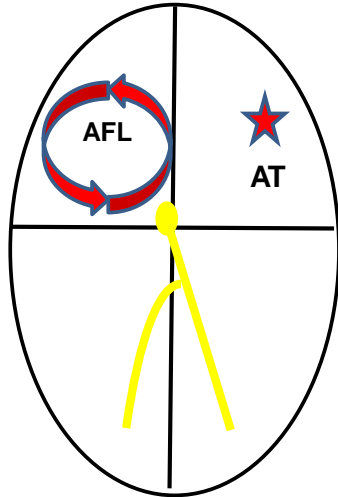


Pseudo R waves
RP interval = 60ms

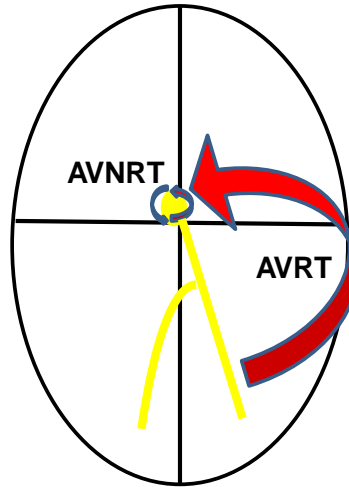
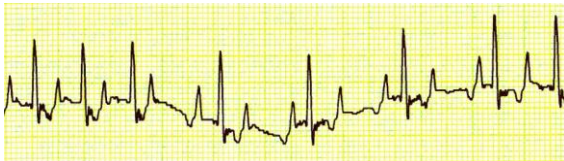

No P waves visible; possible pseudo-S waves in AVF (retrograde P)

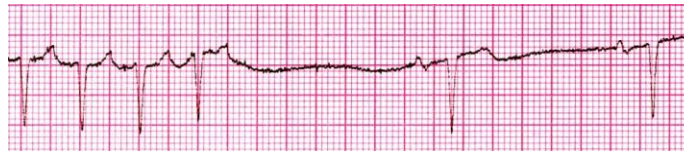Carotid sinus massage/Valsalva manouevre



Atrial flutter or atrial tachycardia are AV nodal independent tachycardias. Carotid massage causes transient AV block which reveals underlying P waves

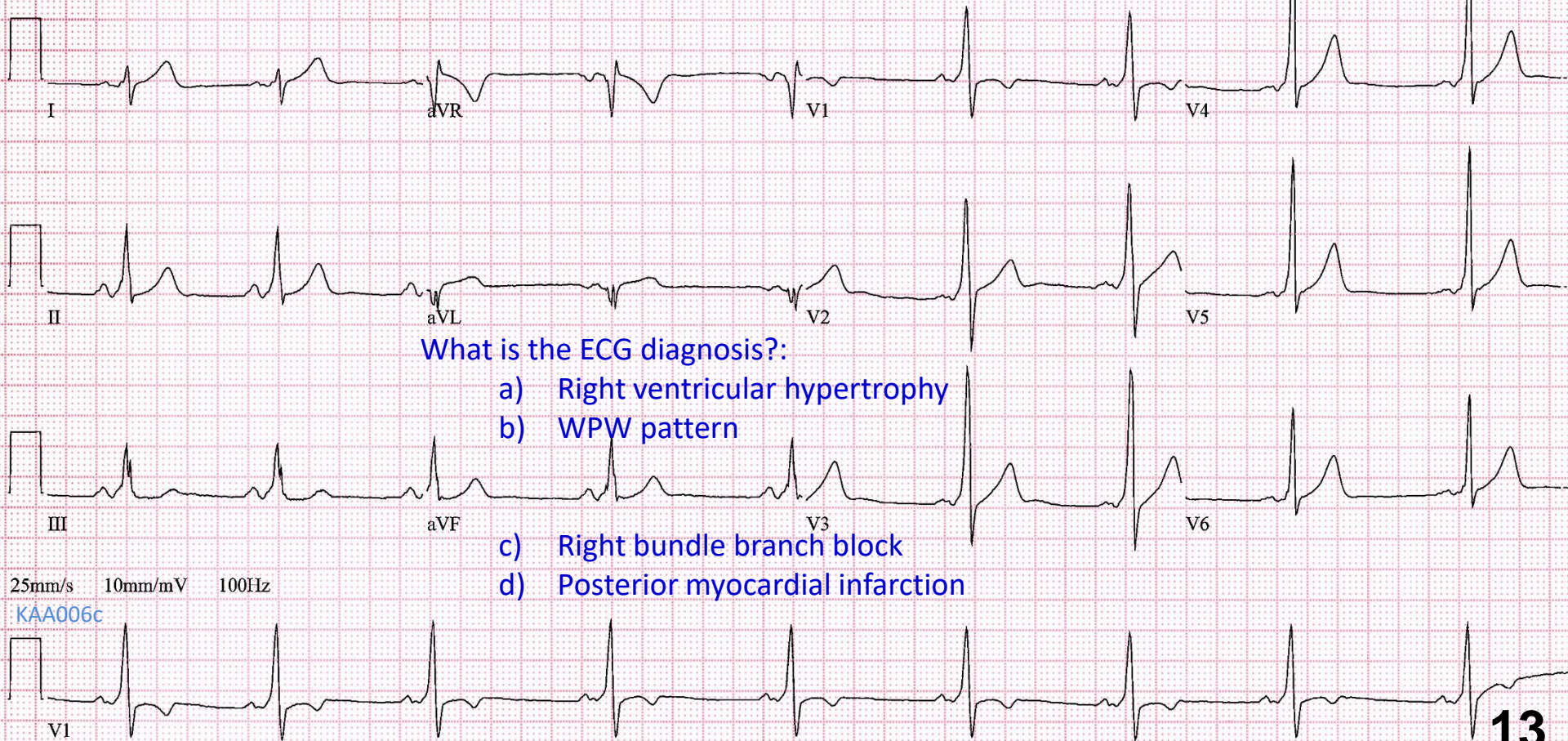


AVJRT (AVNRT/AVRT) are AV nodal dependent tachycardias. Carotid massage CSM may terminate the tachycardia



Useful for terminating the arrhythmia, but also to determine the cause (Valsalva slightly better than CSM) – 20-25% success rate

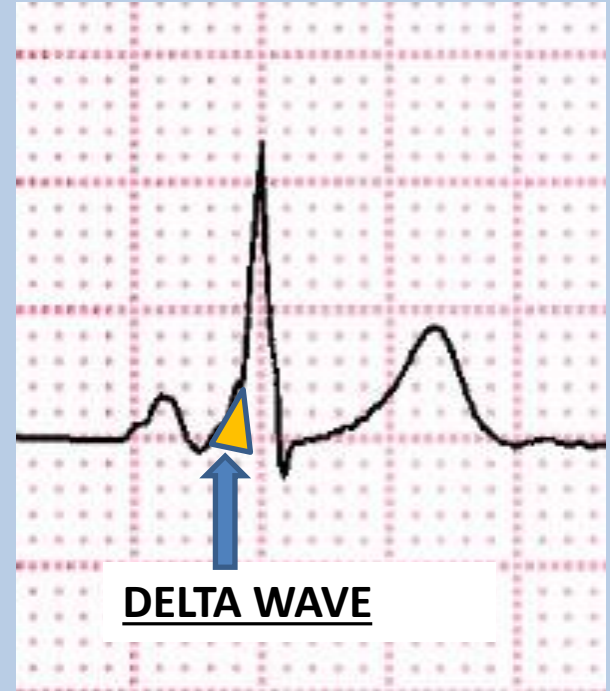
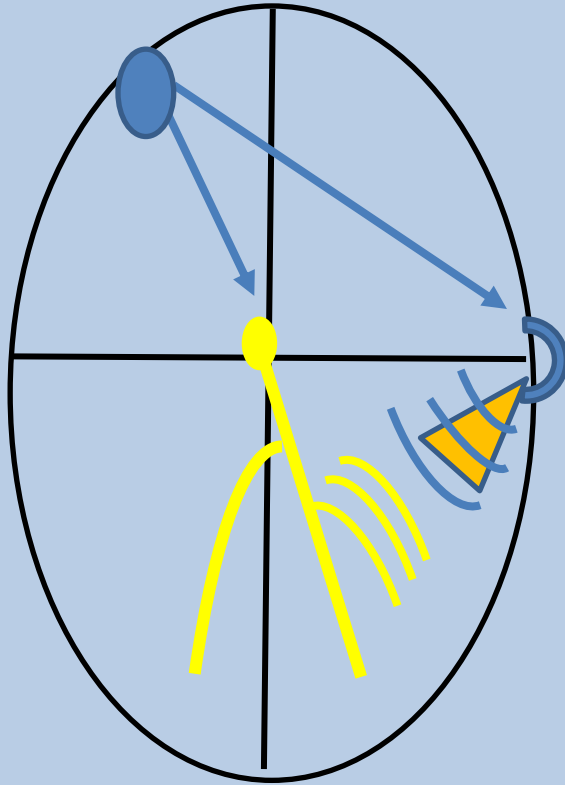
ECG 13



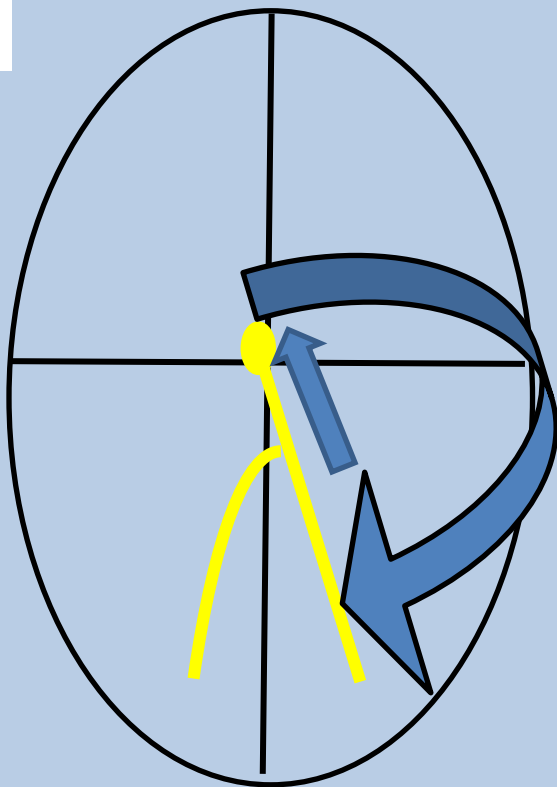
What is the ECG diagnosis?:

- a) Right ventricular hypertrophy
- b) WPW pattern
- c) Right bundle branch block
- d) Posterior myocardial infarction

WPW

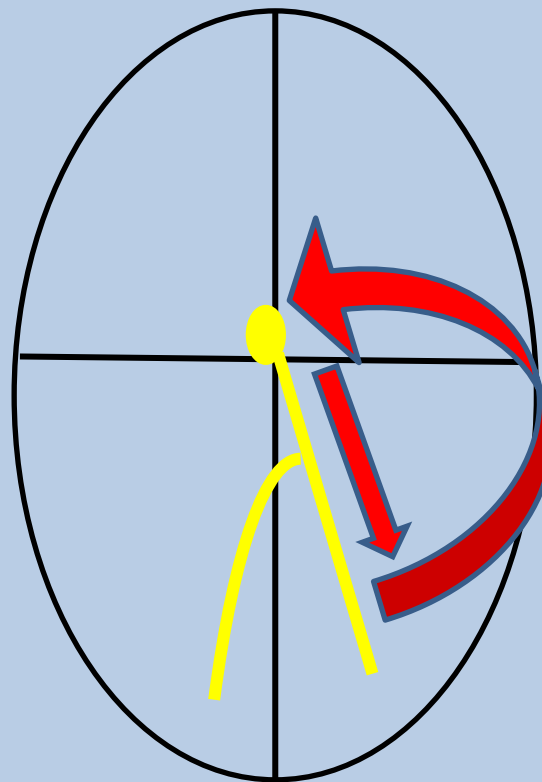


The Delta wave is caused by ventricular pre-excitation, because of rapid conduction over accessory pathway



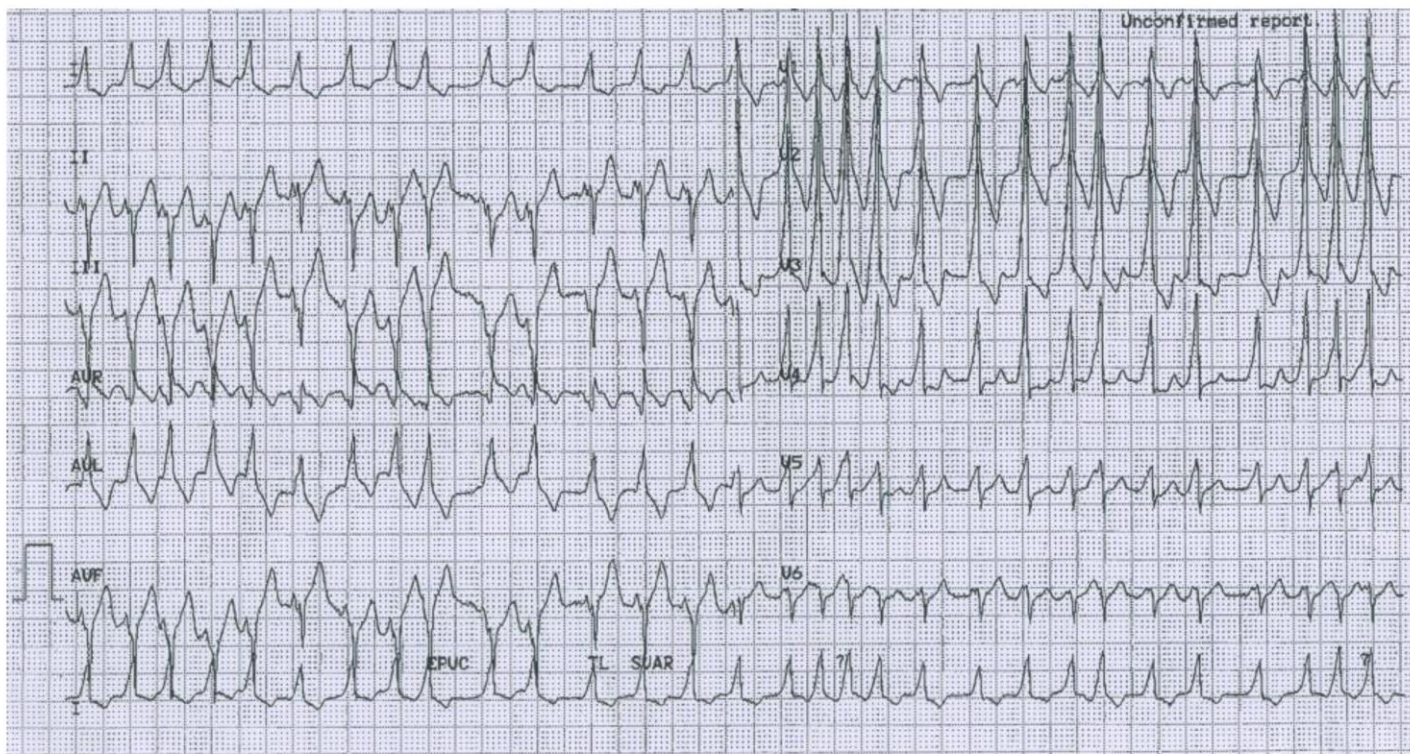
Antidromic AVRT (uncommon)

WIDE COMPLEX TACHYCARDIA

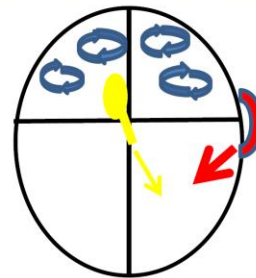


Orthodromic AVRT (common)

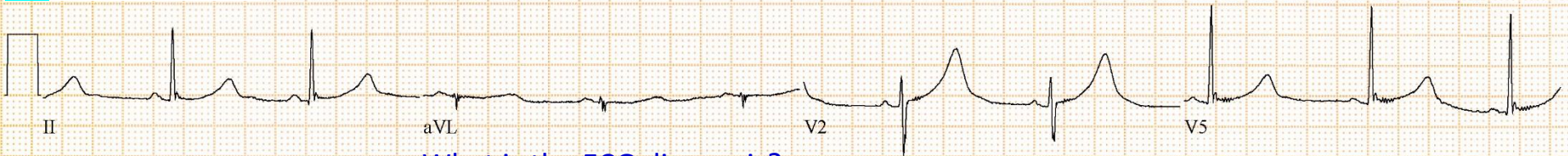
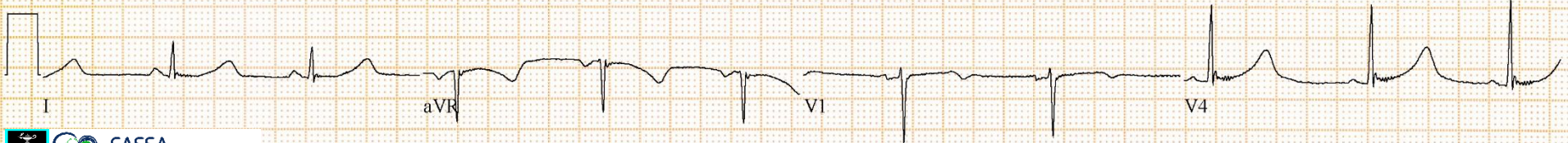
NARROW COMPLEX TACHYCARDIA (USUALLY)



An example of a wide complex, irregular tachycardia. This is pre-excited atrial fibrillation over a left lateral accessory pathway. Note that the QRS complexes are wide and vary in morphology because of variable degrees of fusion over the accessory pathway and the AV node.

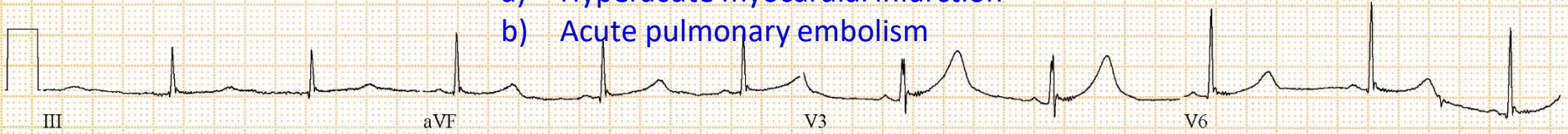


ECG 14



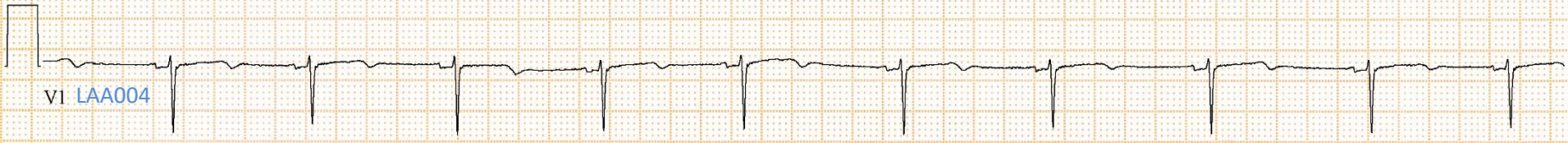What is the ECG diagnosis?:

- a) Hyperacute myocardial infarction
- b) Acute pulmonary embolism



- c) Long QT syndrome
- d) Acute hyperkalaemia

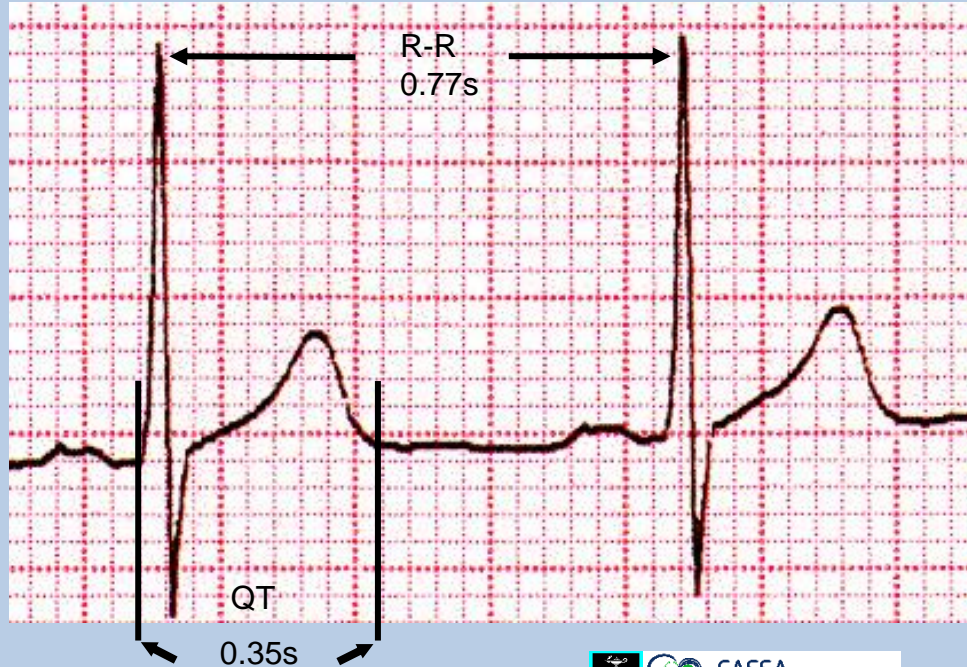
25mm/s 10mm/mV 150Hz



QT interval

Q-T: measure from beginning of the QRS to the end of T wave

Measure the longest QT – usually V2 – V4



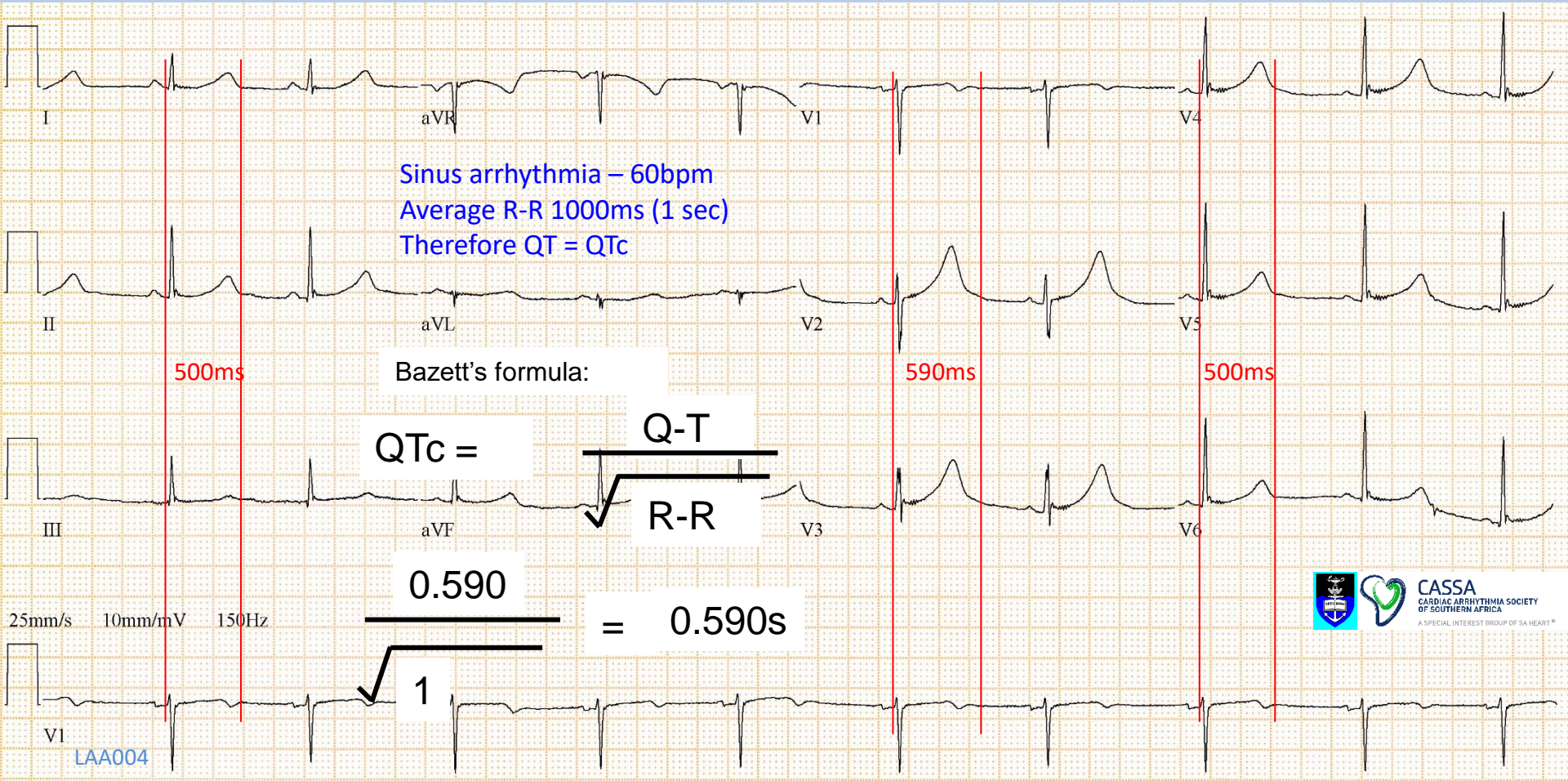
Correct using Bazett's formula - measurements in seconds

$$QTc = \frac{QT}{\sqrt{R-R}}$$
$$\frac{0.35s}{\sqrt{0.77s}} = 0.39s$$

Normal QTc:

≤ 0.44s (440ms) – males

≤ 0.46s (460ms) - females



ECG of a 22 year old woman with LQTS type I



Assessing risk of drugs that prolong the QT interval and cause arrhythmias.

A Trusted Partner Providing Reliable Information On Medicines

FOR EVERYONE

FOR HEALTHCARE PROVIDERS

FOR RESEARCH SCIENTISTS

CredibleMeds > QTDrugs Lists (registration required)

Print Share RSS Donate

Select Medicines of Interest

AVAILABLE TDP RISK CATEGORIES

You can select multiple categories.

- Known Risk of TdP** [more info](#)
- Possible Risk of TdP** [more info](#)
- Conditional Risk of TdP** [more info](#)
- Drugs to Avoid in Congenital Long QT** [more info](#)



SELECTED TDP RISK CATEGORIES

- Known Risk of TdP** [Remove](#)

<https://www.crediblemeds.org/index.php/login/dlcheck>

Results:

Show 10 entries Export Options: Copy Excel Print PDF Search:

Generic Name	Brand Names (Partial List)	Drug Class	Therapeutic Use	PubMed Search	Risk Category
Amiodarone	Cordarone®, Pacerone®, Nexterone®	Anti-arrhythmic	Abnormal heart rhythm	LINK	

There are more than 160 drugs now known to prolong QT.

At last count, 59 definitely cause TdP.

259 should be avoided in LQTS

